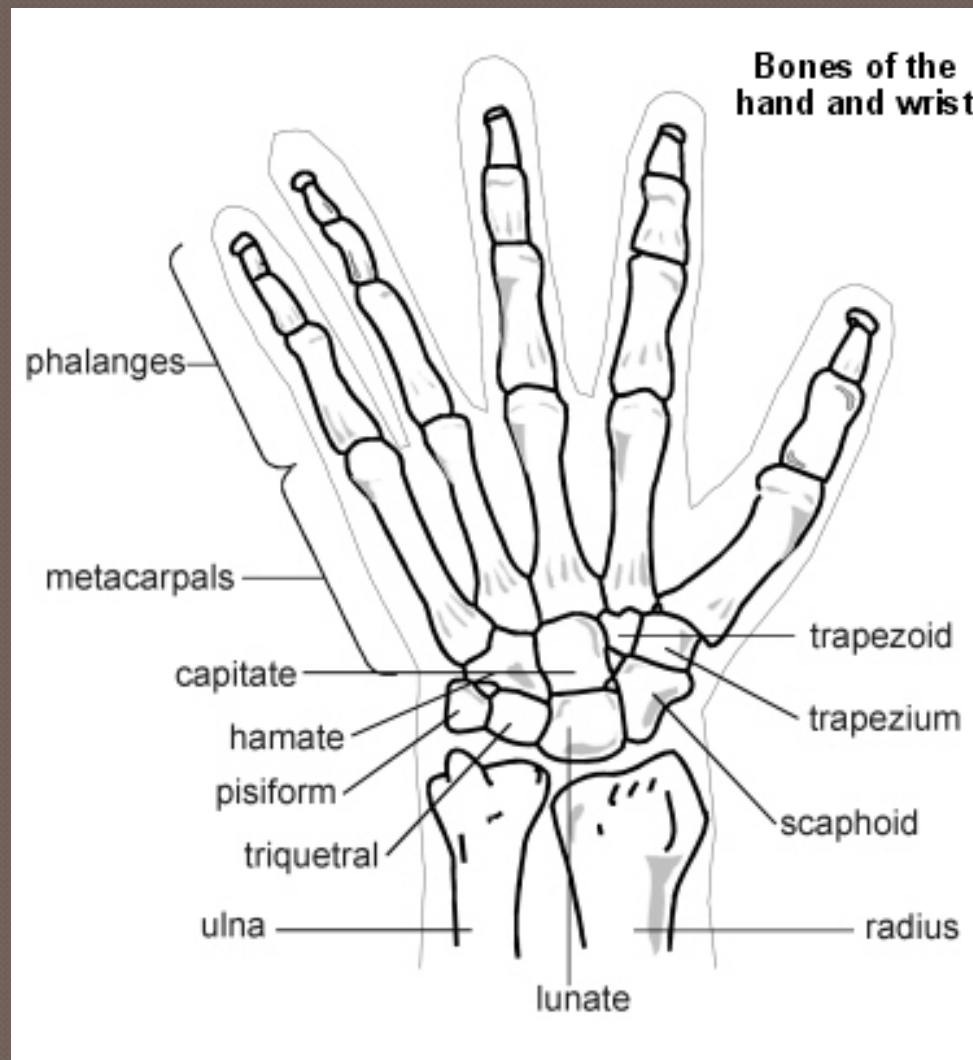


The Hand

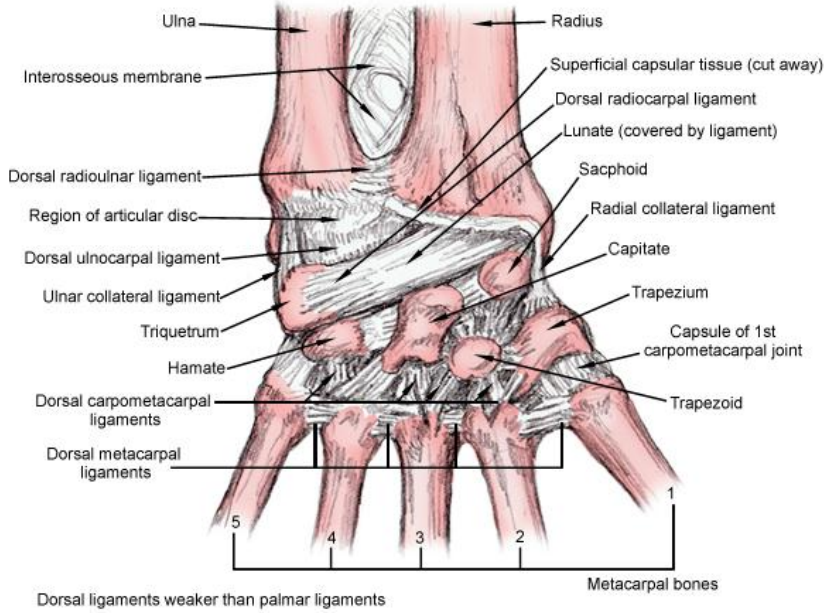


Anatomy



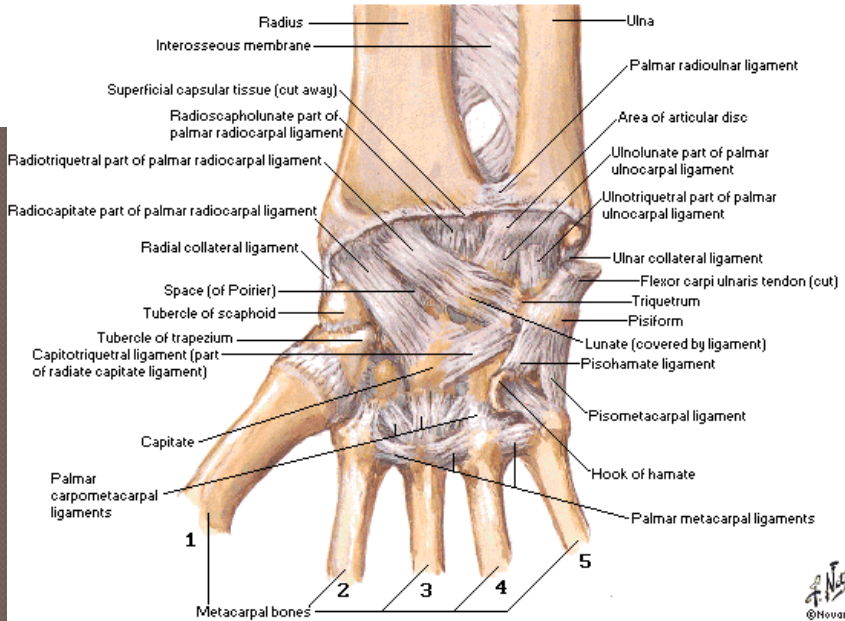
Anatomy

Ligaments of the wrist posterior (dorsal) view



Ligaments of Wrist

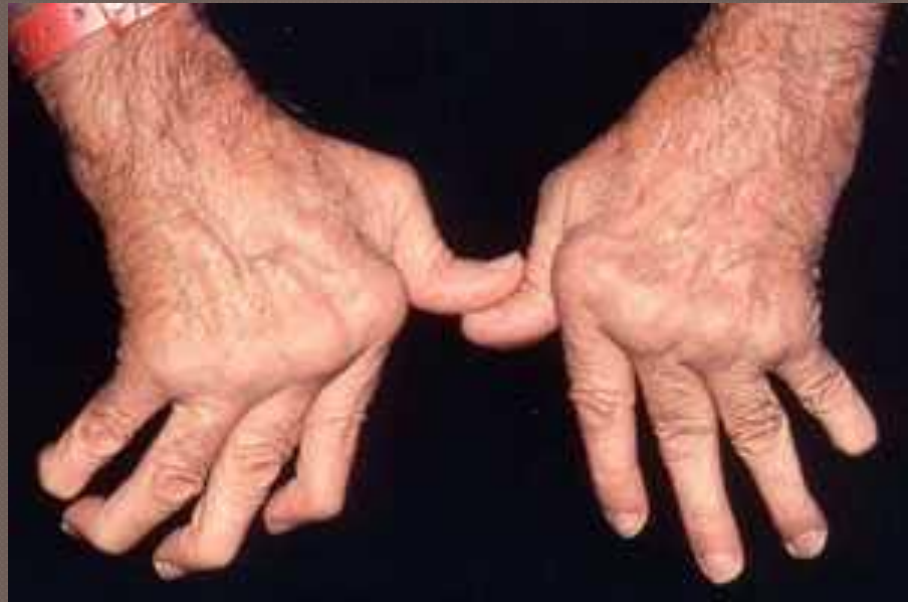Flexor Retinaculum Removed - Palmar View



Physical Exam


○ Inspection:

- Alignment
- Masses
- Swelling
- Bruising



Physical Exam

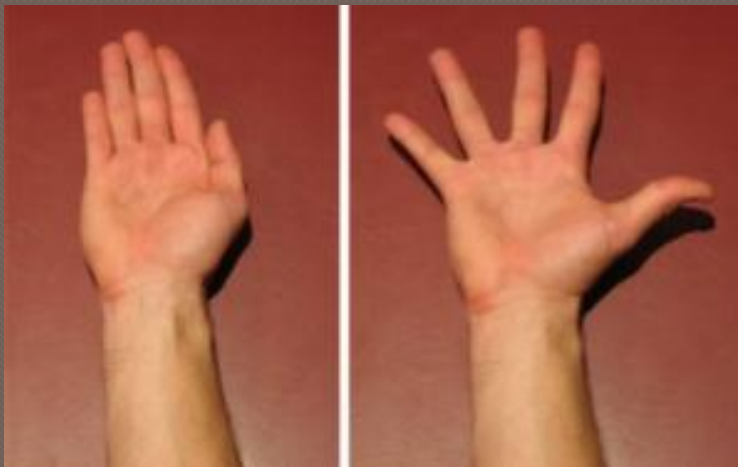
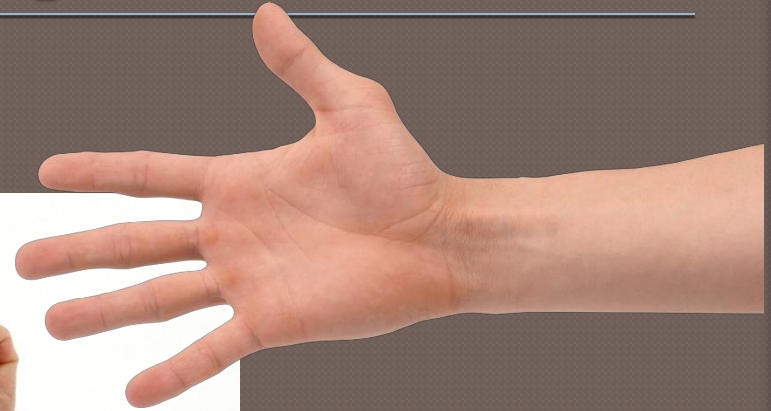● Palpation



Physical Exam

◉ Range of Motion

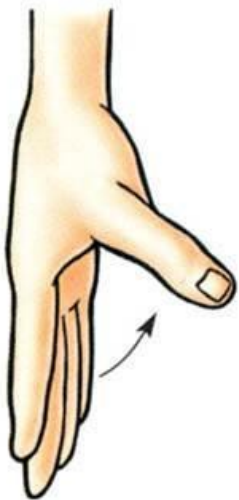
- Flexion
- Extension
- Abduction
- Adduction



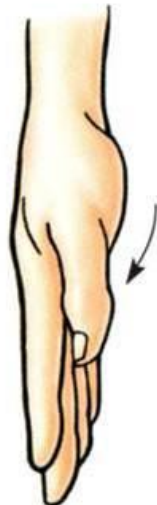Physical Exam

◉ Thumb range of motion

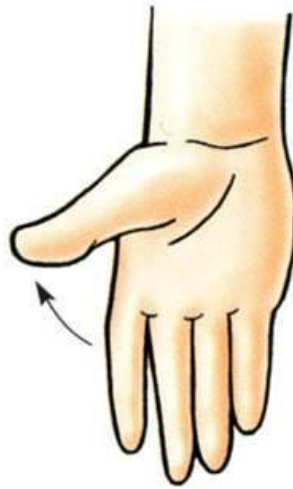- Flexion
- Extension
- Opposition
- Abduction
- Adduction



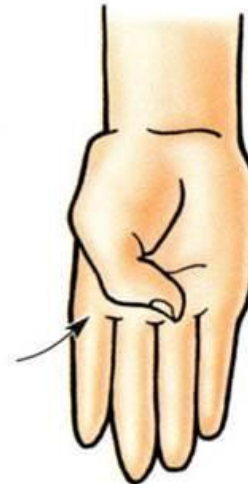Abduction



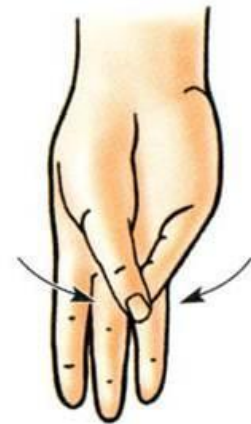Adduction



Extension




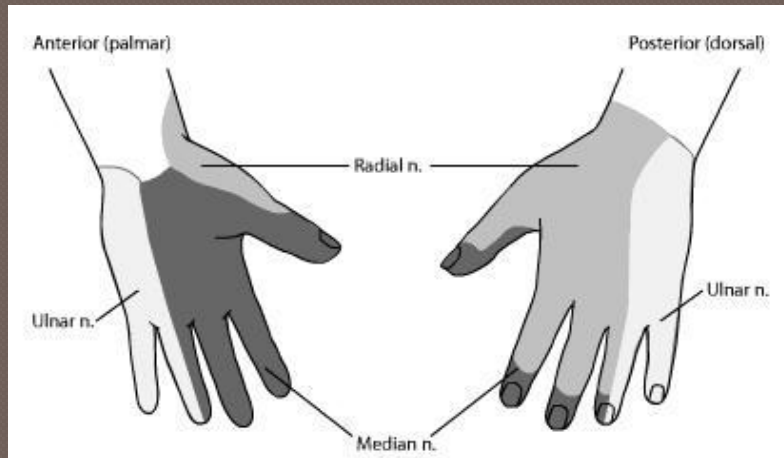
Flexion



Opposition

Physical Exam

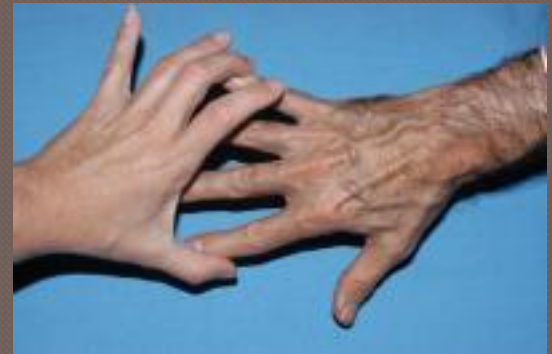○ Neuro exam



Median



Radial

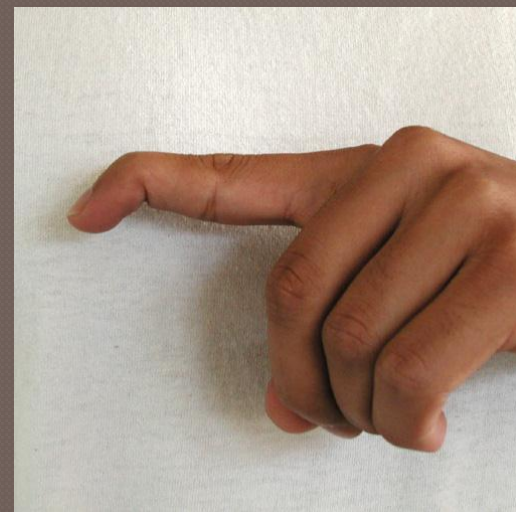
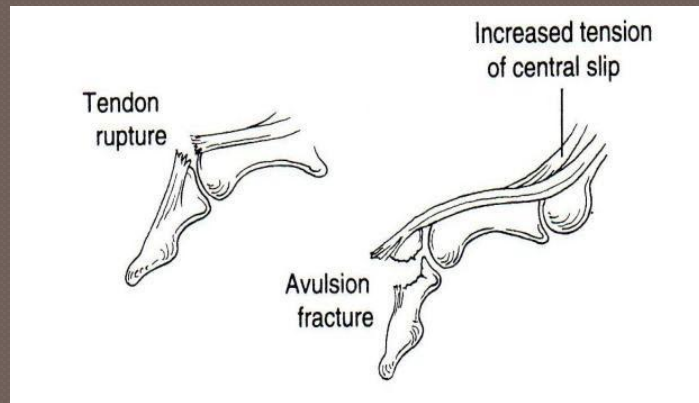


Ulnar

Hand Injuries

○ Mallet finger

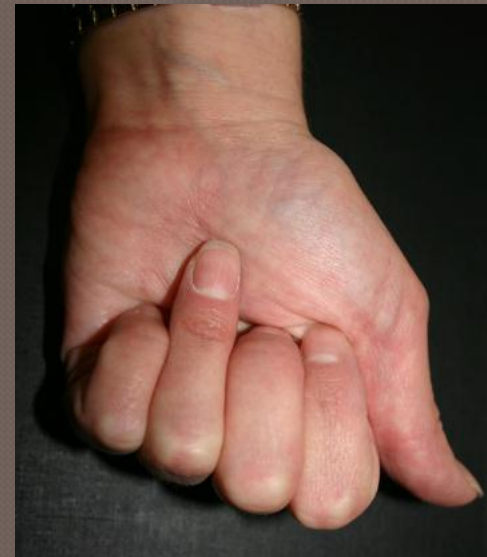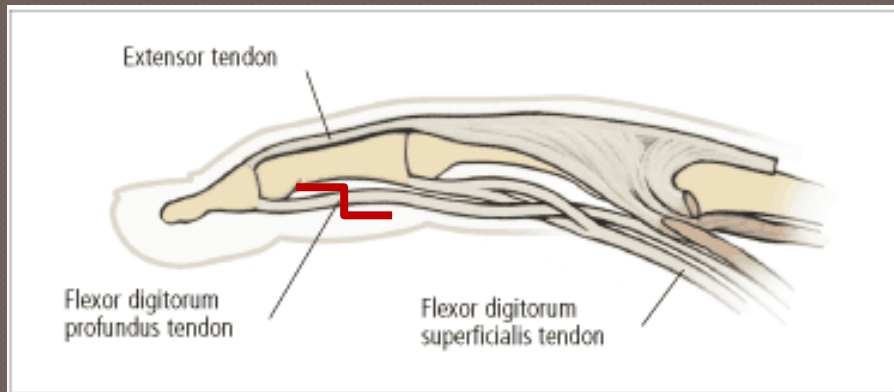
- Disruption of the extensor tendon at the DIP joint
- Patient is unable to actively extend distal phalanx
- Treatment is splinting in extension for 6-8 weeks



Hand Injuries

◉ Jersey finger

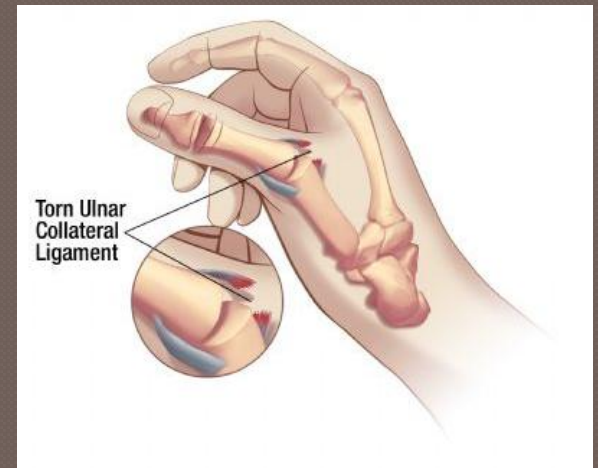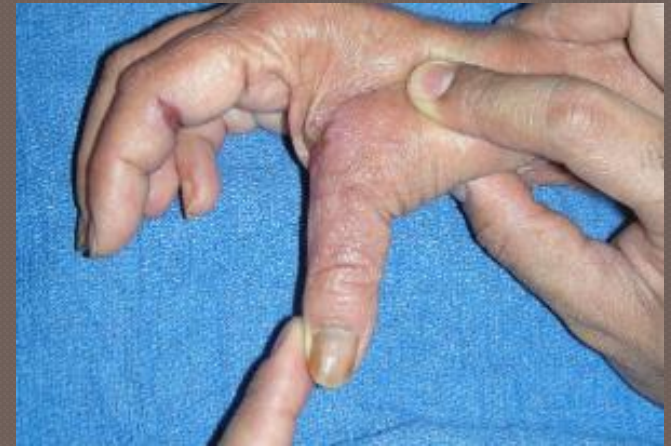- Rupture of the flexor tendon
- Patient is unable to flex the DIP joint
- All need to be referred to surgery to fix



Hand Injuries

○ Thumb UCL tear

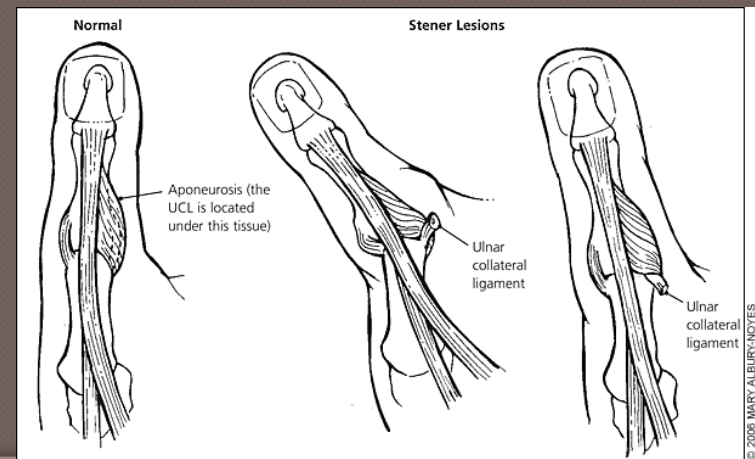
- At MCP joint
- Mechanism: forced abduction and hyperextension
- Exam shows increased laxity on valgus stress
- Uncomplicated tears can be managed with thumb spica splint immobilization



Hand Injuries

○ Thumb UCL tear

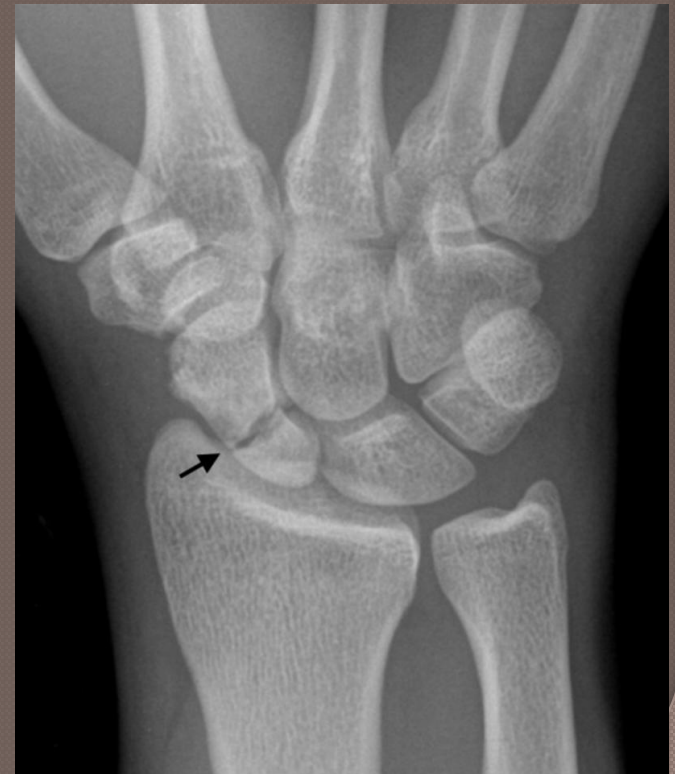- Surgical referral
 - Avulsion fracture with $>2\text{mm}$ displacement
 - Avulsion fracture involving $>10\text{-}12\%$ of the articular surface
 - Valgus testing with >30 degrees of laxity or $15\text{-}20$ degrees greater than the other thumb
- Stener lesion



Hand Injuries

○ Scaphoid fracture

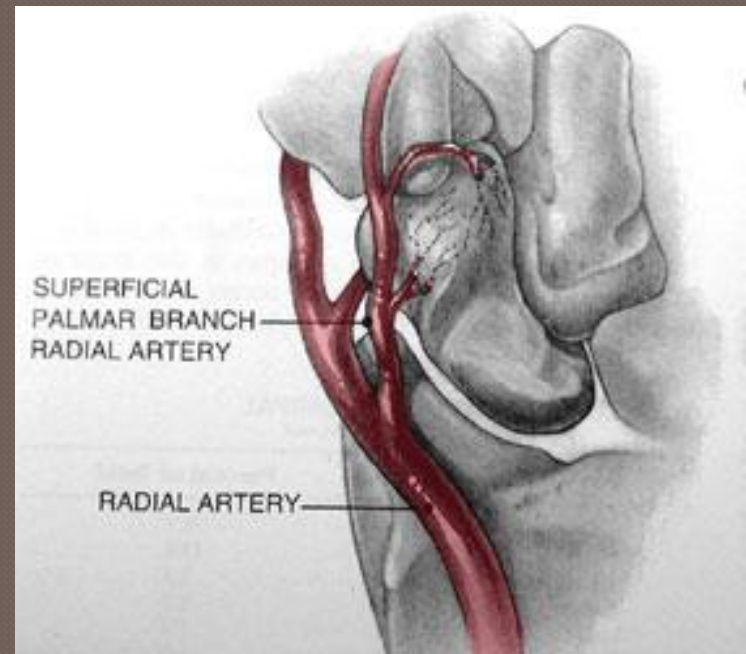
- Fall on an outstretched hand
- Snuff box tenderness on exam
- Can be difficult to see on x-ray
 - Can cast for 7-10 days or CT



Hand Injuries

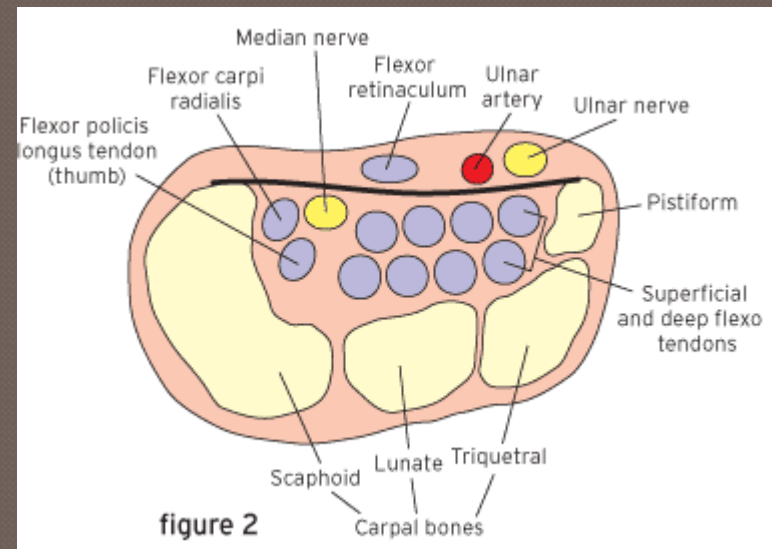
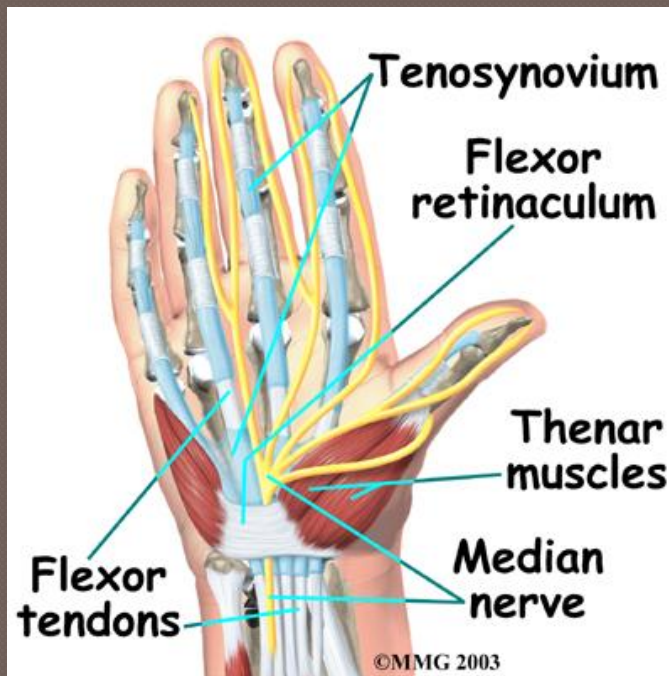
○ Scaphoid fracture

- Blood supply
 - Tenuous
 - From distal to proximal
 - High risk for AVN and non-union
- Treatment
 - Immobilization vs. surgical



Hand Pain

- Carpal Tunnel Syndrome
 - Median nerve compression



Hand Pain

○ Carpal Tunnel Syndrome

- Symptoms
 - Numbness and tingling in ulnar nerve distribution
 - Worse at night or with sustained position
 - Weakness or clumsiness of hand
- Exam findings
 - Atrophy of thenar eminence
 - Weakness of thumb abduction and opposition
 - Decreased sensation over median nerve (late finding)
- Can use NCS to help diagnose

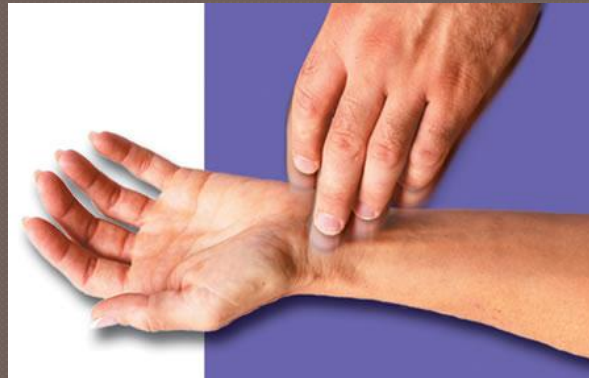Hand Pain

○ Carpal Tunnel Syndrome

- Provocative tests
 - Phalen



- Tinnel



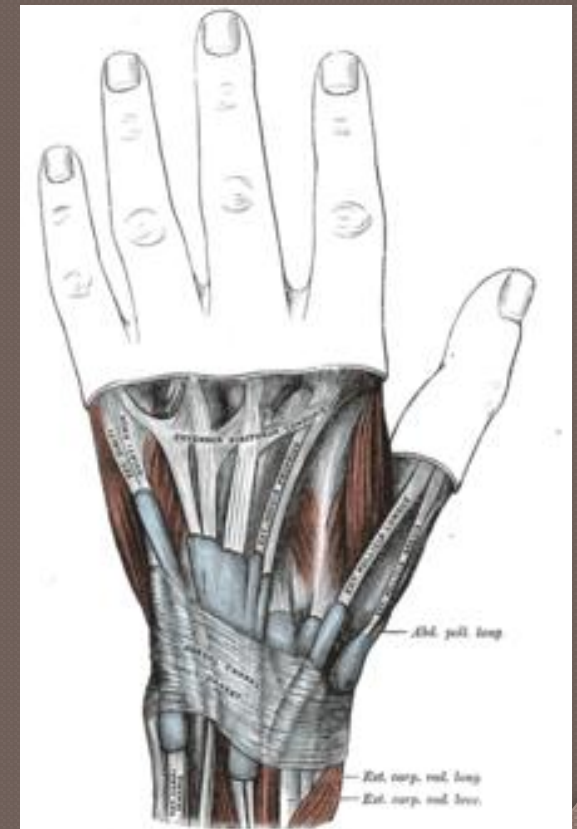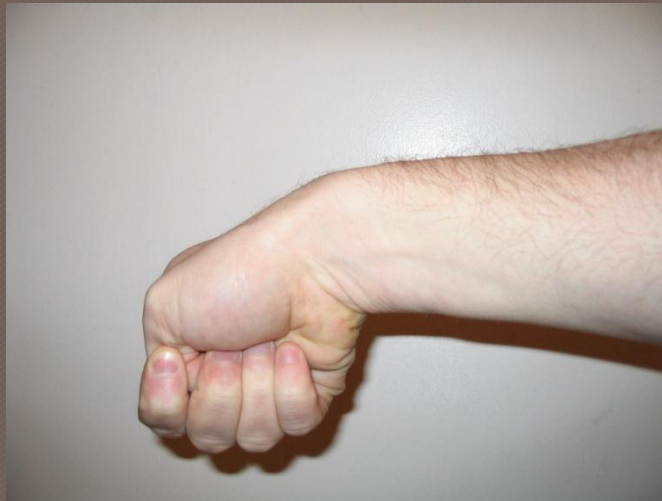Hand Pain

○ Carpal Tunnel Syndrome

- Treatment
 - Night splints
 - Avoid wrist flexion
 - Cortisone injections
 - Release surgery

Hand Pain

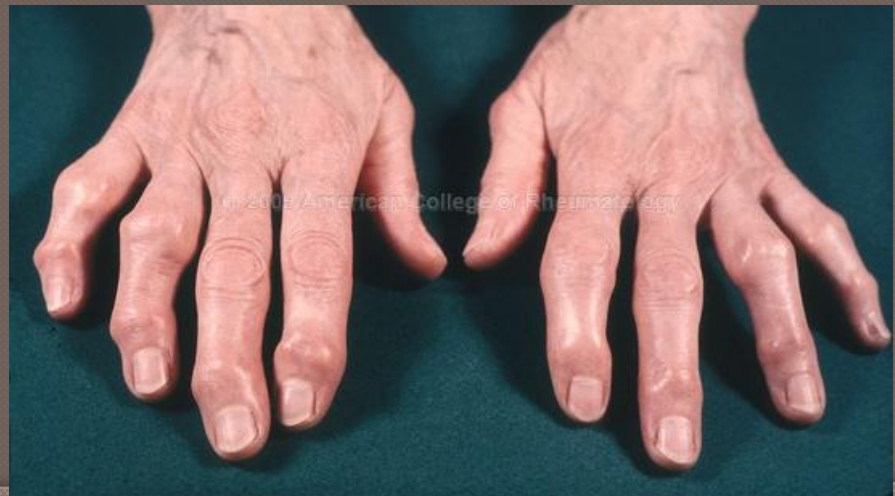- ◉ De Quervain's tenosynovitis
 - Irritation of the extensor pollicis brevis and abductor pollicis longus
 - Positive Finkelstein's test



Hand Pain

○ Osteoarthritis

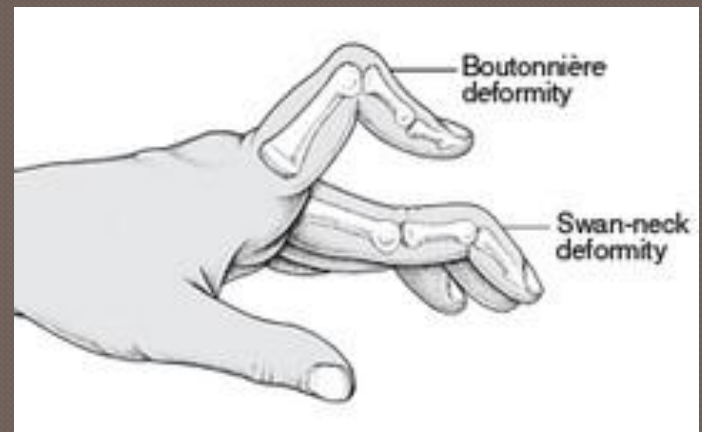
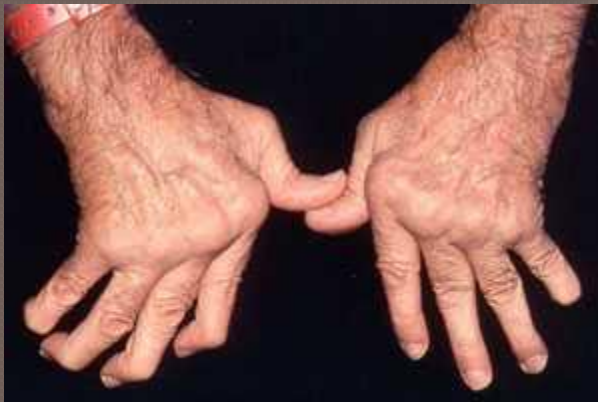- Symptoms: decreased ROM, stiffness, swelling, morning symptoms
- Most commonly involves thumb CMC, PIPs (Bouchard's nodes), and DIPs (Heberden's)
- Joint space narrowing, osteophytes, and bone spurs on x-ray



Hand Pain

○ Rheumatoid arthritis

- Symptoms: swelling, stiffness, erythema, systemic symptoms
- Most commonly affects MCP
- Associated with deformity due to synovial damage



The Hand

- ◉ Anatomy: complicated, focus on key structures
- ◉ Physical exam: assess symptoms and guides differential
- ◉ Pain: acute vs. chronic, injury vs. disease process

Questions?