

## CLINICAL PRACTICE

## Croup

James D. Cherry, M.D., M.Sc.

*This Journal feature begins with a case vignette highlighting a common clinical problem. Evidence supporting various strategies is then presented, followed by a review of formal guidelines, when they exist. The article ends with the author's clinical recommendations.*

Crouplike symptoms develop in a previously healthy 2-year-old girl at 11 p.m. She is seen in an emergency department 2 hours later with a barking cough and, when upset, inspiratory stridor. Her temperature is 36.1°C, respiratory rate 20 breaths per minute, heart rate 151 beats per minute, and oxygen saturation 94% while she is breathing ambient air. She has mild sternal retractions but no cyanosis. How should she be evaluated and treated?

## THE CLINICAL PROBLEM

Before the 20th century, all crouplike illnesses were thought to be diphtheria.<sup>1</sup> Today, the word “croup” is used to refer to a number of respiratory illnesses that are characterized by varying degrees of inspiratory stridor, barking cough, and hoarseness due to obstruction in the region of the larynx.<sup>1-4</sup>

## CLASSIFICATION

The terminology for croup illnesses has evolved over time, but unfortunately, some classifications have been imprecise.<sup>1-7</sup> For example, the term “laryngotracheobronchitis” is often used to describe either spasmodic croup or laryngotracheitis. A classification scheme with definitions and clinical features is presented in Table 1. The vast majority of cases of croup are either laryngotracheitis or spasmodic croup.<sup>8</sup>

## EPIDEMIOLOGIC FEATURES

Croup (laryngotracheitis and spasmodic croup) is an illness of infants and children younger than 6 years of age,<sup>9,10</sup> with a peak incidence between 7 and 36 months of age. During the second year of life, about 5% of children have croup. The incidence in boys is about 1.5 times that in girls. In a 14-year study of hospitalizations for croup in Ontario, Canada, between 1988 and 2002, a biennial midautumn peak and an annual summer trough were observed.<sup>10</sup>

## PATHOLOGICAL FEATURES AND PATHOGENESIS

In acute laryngotracheitis, there is erythema and swelling of the lateral walls of the trachea, just below the vocal cords.<sup>11,12</sup> Histologically, the involved area is edematous, with cellular infiltration in the lamina propria, submucosa, and adventitia. The infiltrate contains histiocytes, lymphocytes, plasma cells, and neutrophils.<sup>13,14</sup> In bacterial croup — laryngotracheobronchitis and laryngotracheobronchopneumonitis — the tracheal wall is infiltrated with inflammatory cells, and in addition, ulceration, pseudomembranes, and microabscesses are present.<sup>2,15</sup> There is thick pus within the lumen of the trachea and the lower air passages.<sup>2,16</sup> In spasmodic croup, there is noninflammatory edema in the subglottic region.<sup>11</sup>

From the Division of Infectious Diseases, Mattel Children's Hospital UCLA, and the Department of Pediatrics, David Geffen School of Medicine at UCLA — both in Los Angeles. Address reprint requests to Dr. Cherry at the Dept. of Pediatrics, David Geffen School of Medicine at UCLA, 10833 Le Conte Ave., MDCC 22-442, Los Angeles, CA 90095-1752, or at [jcherry@mednet.ucla.edu](mailto:jcherry@mednet.ucla.edu).

N Engl J Med 2008;358:384-91.  
Copyright © 2008 Massachusetts Medical Society.

**Table 1. Classification, Definition, and Clinical Features of Croup Illnesses.**

Definition and Characteristic	Spasmodic Croup	Acute Laryngotracheitis	LTB and LTBP (Including Bacterial Tracheitis)*	Laryngeal Diphtheria
Definition	Sudden nighttime onset of inspiratory stridor; associated with mild upper respiratory tract infection, without inflammation	Inflammation of the larynx and trachea	Inflammation of the larynx, trachea, and bronchi or lung; usually similar in onset to laryngotracheitis, but with more severe illness	Infection involving the larynx and other areas of the airway due to <i>Corynebacterium diphtheriae</i> , resulting in progressive airway obstruction
Typical age at occurrence	3 mo to 3 yr	3 mo to 3 yr	3 mo to 3 yr	All ages
Individual and family history	Possible family history of croup; possible previous attack	Possible family history of croup	Possible family history of croup	Lack of immunization or inadequate immunization
Prodrome	Minimal coryza	Usually coryza	Usually coryza	Usually pharyngitis
Onset (time to full-blown disease)	Sudden, always at night; the characteristic presentation is that of a child who at bedtime was thought to be well or perhaps to have mild cold symptoms but who awakened suddenly with croupy cough and stridor	Moderately rapid but variable; onset mimics that of a cold, with nasal irritation, cough, and coryza; fever occurs within the first 24 hr; within 12 to 48 hr, signs of obstructed upper airway and symptoms occur	Usually gradually progressive over a period of 12 hr to 7 days	Slow, progressing over a period of 2 to 3 days
Symptoms on presentation	Hoarseness and barking cough, no dysphagia, minimal-to-moderate inspiratory stridor; nontoxic presentation	Hoarseness and barking cough, no dysphagia, minimal-to-severe inspiratory stridor; usually minimally toxic presentation	Hoarseness and barking cough; no dysphagia; inspiratory stridor, usually severe; typically toxic presentation	Hoarseness and barking cough; usually dysphagia; minimal-to-severe inspiratory stridor; usually nontoxic presentation
Signs on presentation	No fever; no pharyngitis; normal epiglottis	Fever, generally 37.8 to 40.5°C; usually minimal pharyngitis; normal epiglottis	Fever, generally 37.8 to 40.5°C; usually minimal pharyngitis; normal epiglottis	Fever, generally 37.8 to 38.5°C; membranous pharyngitis; epiglottis usually normal but may contain membrane
Radiographic findings	Subglottic narrowing on posterior–anterior view	Subglottic narrowing on posterior–anterior view	Subglottic narrowing on posterior–anterior view, irregular soft-tissue densities in trachea on lateral view, bilateral pneumonia	Not useful
White-cell count	Normal	Mildly elevated, with >70% polymorphonuclear cells	Usually elevated or abnormally low, with >70% neutrophils and increased percentage of band forms	Usually elevated, with increased percentage of band forms
Microbiologic findings	Etiologic agents similar to those in laryngotracheitis	Most commonly caused by parainfluenza virus 1 (responsible for frequent fall outbreaks); many other viruses also implicated, including other parainfluenza viruses and influenza viruses (influenza virus A and parainfluenza virus 3 often cause severe cases), respiratory syncytial virus, measles virus, adenoviruses, and rhinoviruses	Although may be caused by a virus (e.g., parainfluenza virus 1, 2, or 3 or influenza virus A or B), in most instances the illness is due to secondary bacterial infection, particularly from <i>Staphylococcus aureus</i> ; other bacteria include group A streptococci, <i>Streptococcus pneumoniae</i> , <i>Haemophilus influenzae</i> , and <i>Moraxella catarrhalis</i>	<i>C. diphtheriae</i> (identified on smear and culture of membrane)

\* LTB denotes laryngotracheobronchitis, and LTBP laryngotracheobronchopneumonitis.

**Table 2. Assessment of the Severity of Croup.\***

Level of Severity†	Characteristics
Mild	Occasional barking cough; no audible stridor at rest, and either mild or no suprasternal or intercostal indrawing (retractions of the skin of the chest wall)
Moderate	Frequent barking cough, easily audible stridor at rest, and suprasternal and sternal retractions at rest, but little or no agitation
Severe	Frequent barking cough, prominent inspiratory and, occasionally, expiratory stridor, marked sternal retractions, and agitation and distress
Impending respiratory failure	Barking cough (often not prominent), audible stridor at rest (occasionally hard to hear), sternal retractions (may not be marked), lethargy or decreased level of consciousness, and often dusky appearance in the absence of supplemental oxygen

\* Adapted from the Alberta Medical Association.<sup>4</sup>

† Corresponding Westley scores for level of severity would be 0 to 2 for mild croup, 3 to 5 for moderate croup, 6 to 11 for severe croup, and 12 to 17 for impending respiratory failure.<sup>8</sup>

Host factors appear to be important in pathogenesis, since parainfluenza virus infections (particularly type 3) are common in infants and young children,<sup>17</sup> yet croup develops in only a small percentage of those exposed.<sup>18</sup> A number of studies have indicated that allergic factors play a role in recurrent croup.<sup>5,19,20</sup> It is possible that primary infection with parainfluenza virus type 3 (which may go unrecognized) leads to sensitization to the parainfluenza virus group rather than to type 3 alone,<sup>5</sup> setting the stage for spasmodic croup due to parainfluenza virus types 1 and 2.

## STRATEGIES AND EVIDENCE

### EVALUATION

#### *Differential Diagnosis*

Since the croup illnesses discussed above and presented in Table 1 differ in severity as well as in their treatment, the differential diagnosis is important. Correct diagnosis of other acute obstructive illnesses in the region of the larynx (e.g., epiglottitis, foreign body, angioneurotic edema of the epiglottis) is also essential and lifesaving.<sup>2,6</sup>

Epiglottitis rather than croup is suggested by the absence of a croupy cough (which sounds similar to a barking seal or sea lion); the sitting posture of the child, with the chin pushed forward and a reluctance or refusal to lie down; and greater apprehension and anxiety on the part of

the child than the degree of inspiratory difficulty would suggest. A lateral neck radiograph will confirm the diagnosis of epiglottitis but is rarely necessary, since the clinical findings noted above are often diagnostic.

Both foreign-body and angioneurotic edema can cause upper-airway obstruction. They usually occur suddenly, without fever or other signs and symptoms of infection.

Laryngotracheobronchitis and laryngotracheobronchopneumonia can be differentiated from spasmodic croup and laryngotracheitis by signs of lower-airway involvement (crackles, air trapping, wheezing, and pneumonia seen on a radiograph).<sup>2,6,15,21,22</sup> A bacterial cause should be suspected in these cases and also in cases of laryngotracheitis when symptoms and signs persist or worsen despite treatment with corticosteroids and epinephrine. In both laryngotracheobronchitis and laryngotracheobronchopneumonia, a lateral neck radiograph may reveal soft densities indicating purulent exudate within the trachea. Laryngeal diphtheria should be considered in unimmunized patients with possible exposure.

Laboratory studies are rarely useful in the evaluation of routine croup. If clinical findings suggest laryngotracheobronchitis or laryngotracheobronchopneumonia, white-cell and differential counts and posterior–anterior and lateral chest and neck radiographs are indicated. In these cases, intubation is commonly required, and a tracheal bacterial culture should be obtained at the time of intubation. Also useful in cases of laryngotracheobronchitis or laryngotracheobronchopneumonia, as well as in severe cases of laryngotracheitis, is a specimen (from nasal wash or tracheal secretions) for the direct identification of influenza virus, which can help guide decisions about the use of antiviral therapy.

#### *Assessment of Severity*

A variety of scoring systems have been developed to evaluate the severity of croup.<sup>8,23,24</sup> The most commonly used scoring system has been that of Westley et al.,<sup>24</sup> which evaluates the severity of croup by assessing five factors: level of consciousness, cyanosis, stridor, air entry, and retractions. This system has been extremely valuable in treatment trials but has little use in the routine clinical setting.<sup>8</sup> However, a clinically useful severity-assessment table has been developed by an Alberta Clinical Practice Guideline Working Group<sup>4</sup> (Ta-

ble 2). Based on this classification scheme, 85% of children seen in 21 general emergency departments in Alberta, Canada, had mild croup, and less than 1% had severe croup.<sup>8</sup>

#### TREATMENT

During the past 50 years, there has been considerable controversy regarding many therapies for croup, including the role of humidified air and the optimal type (warm vs. cold) and the roles of corticosteroids and racemic epinephrine.<sup>2</sup> However, the marked success of corticosteroids in the outpatient management of croup and the effectiveness of nebulized epinephrine in more severe cases have led to the resolution of many of the controversies.

#### *Acute Laryngotracheitis and Spasmodic Croup*

##### Humidified Air

During much of the 20th century, treatment with humidified air (mist therapy) was the cornerstone of the management of croup.<sup>1,2</sup> More recently, however, the effectiveness of mist therapy has been questioned.<sup>4,8,25</sup> In a recent trial<sup>26</sup> comparing the effects of high humidity (100%), low humidity (40%), and blow-by humidity (in which a plastic hose is held near the child's nose and mouth) in children with mild croup, there were no significant differences in the croup-score responses among the three groups; each group had significant improvement (about 33%) over baseline in the croup score 60 minutes after administration. In two other small trials, control subjects who received nebulized saline also had improvement in their croup scores over the baseline values.<sup>23,24</sup> Since none of these studies included an untreated control group, it is not possible to know whether the improvements were due to the moist air. A recent Cochrane Collaboration review of data from three other studies concluded that there was no evidence that inhalation of humidified air in children with mild-to-moderate croup resulted in a substantial improvement in the croup score.<sup>27</sup>

##### Corticosteroid Therapy

Corticosteroid therapy is now routinely recommended by all experts.<sup>4,5,8,10,25</sup> In a cotton-rat laryngotracheitis model,<sup>18</sup> corticosteroids reduced the degree of inflammation and cell damage; although the viral load was increased, the duration of shedding was not prolonged. Meta-analyses of randomized trials<sup>28-30</sup> have consistently demon-

strated significant improvement in patients treated with corticosteroids as compared with controls. For example, in a meta-analysis of 37 trials, patients who were given corticosteroids had significantly lower croup scores at 6 hours, a decrease in return visits, and a decrease in time spent in emergency rooms or hospitals.<sup>30</sup>

Trials of corticosteroids in croup have involved a variety of drugs, dosages, and routes of administration.<sup>30-33</sup> The regimens studied most frequently have been single-dose dexamethasone (0.6 mg per kilogram of body weight given orally or intramuscularly) and nebulized budesonide (2 mg in 4 ml of water); some studies have involved additional doses (up to four doses of dexamethasone or nebulized budesonide given over a period of 2 days). No studies have directly compared the outcomes of single-dose therapy with the outcomes of 2-day treatment schedules.

The 1992 recommendation by the Canadian Paediatric Society to use dexamethasone for treatment was followed by a marked decrease in hospitalizations for croup in Ontario, providing further support for the use of corticosteroids.<sup>10,34,35</sup> Similar findings were noted in Perth, Australia.<sup>36</sup>

A potential concern with corticosteroids, however, is their immunosuppressive effects, which might predispose the patient to infectious complications.<sup>2,5-7</sup> Trials have not been powered to assess these risks, but such complications would be expected to be rare with standard (single-dose) therapy.

##### Epinephrine

Nebulized epinephrine has been extensively studied for the treatment of croup.<sup>2,5,8,23-25,37-42</sup> Early controlled trials demonstrated that the administration of 2.25% racemic epinephrine (0.5 ml in 2.5 ml of saline) by intermittent positive-pressure breathing resulted in a significant reduction in the croup-severity score,<sup>24,37</sup> but this benefit lasted for less than 2 hours. Subsequent trials showed that the administration of racemic epinephrine by nebulization alone was as effective as its administration by intermittent positive-pressure breathing.<sup>41</sup> Later trials also showed that nebulized L-epinephrine diluted in 5 ml of saline at a ratio of 1:1000 was as effective as racemic epinephrine in the treatment of croup.<sup>42</sup> In severe croup, repeated treatments with epinephrine have been used and have often decreased the need for intubation.

## Other Treatments

Children with moderate or severe croup and hypoxia (oxygen saturation while breathing ambient air, <92%) should receive oxygen.<sup>4</sup> This is best administered with the blow-by technique.

A helium–oxygen mixture (heliox) has been shown in a small study to improve croup-severity scores in hospitalized children with croup.<sup>43</sup> However, this treatment was no better — and was more expensive — than treatment with racemic epinephrine.

Antitussive and decongestant agents have not been studied in children with croup, and their use is not indicated.<sup>4</sup> Since laryngotracheitis and spasmodic croup are viral illnesses, there is no reason to treat them with antibiotics unless clinical manifestations or laboratory values suggest secondary bacterial infection. In severe croup due to infection with influenza A or B virus, treatment with neuraminidase inhibitors should be considered, although there are no data demonstrating the efficacy of such treatment in reducing the severity of croup.<sup>44</sup> Since influenza immunization is now routinely recommended for children, the occurrence of croup due to influenza viruses will probably become less common.

*Laryngotracheobronchitis  
and Laryngotracheobronchopneumonitis*

Since most children with laryngotracheobronchitis or laryngotracheobronchopneumonia have bacterial disease, antibiotics should be administered after appropriate cultures have been obtained. Treatment should be directed against *Staphylococcus aureus*, *Streptococcus pyogenes*, *Streptococcus pneumoniae*, *Haemophilus influenzae*, and *Moraxella catarrhalis*. Most cases of laryngotracheobronchitis or laryngotracheobronchopneumonia in children require the placement of a mechanical airway and treatment in an intensive care unit.

## AREAS OF UNCERTAINTY

Efforts are warranted to improve the use of corticosteroids in the treatment of croup. In practice, many children continue to receive prolonged courses of corticosteroids for croup rather than single-dose therapy. I and others have observed viral, bacterial, and fungal complications in association with corticosteroid treatment<sup>2,5-7,45-48</sup>; in all cases, these complications occurred in children who had received multiple doses.

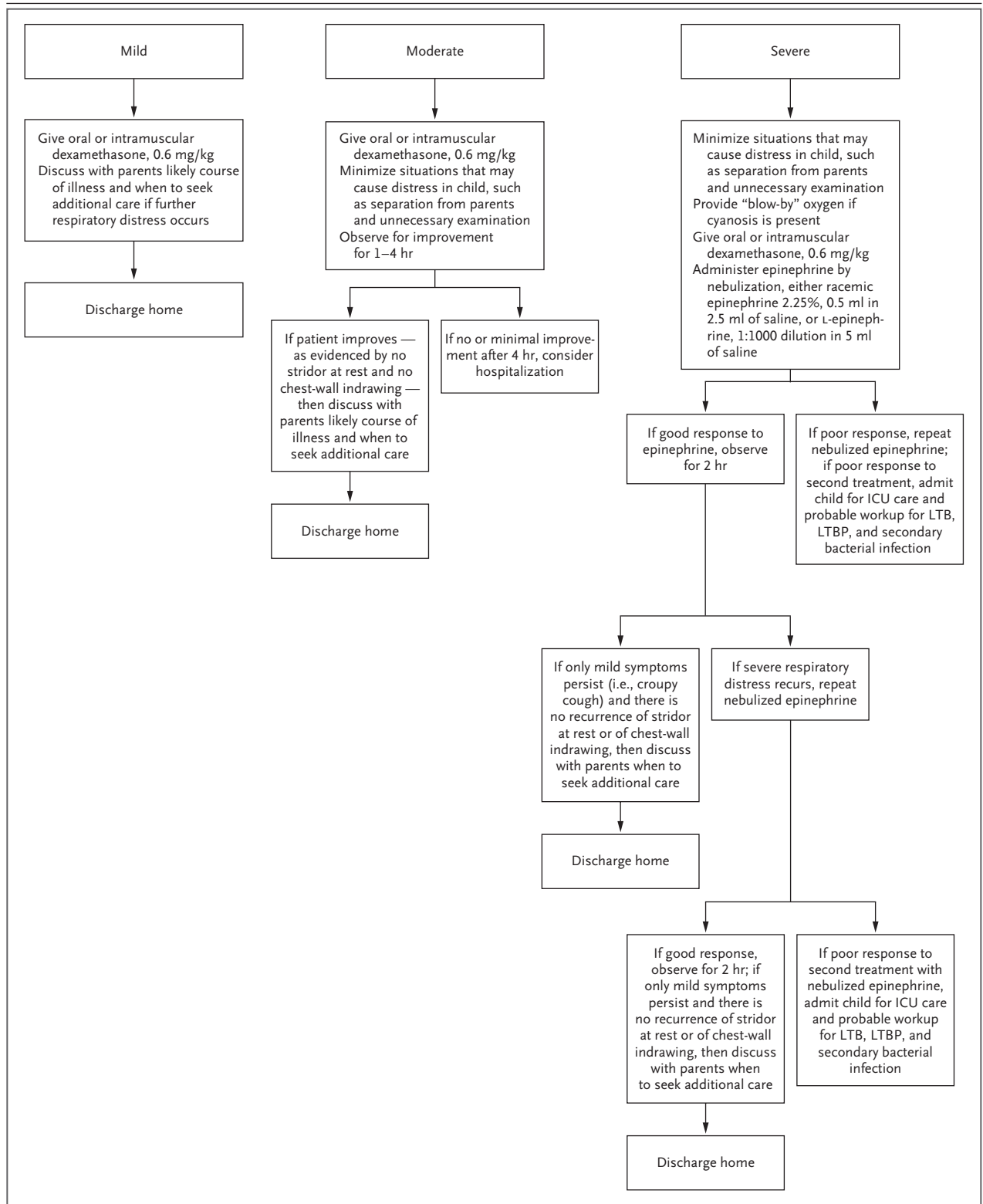
## GUIDELINES

The American Academy of Pediatrics has no guidelines for the management of croup. The Infectious Diseases and Immunization Committee of the Canadian Paediatric Society published a brief statement in 1992, recommending corticosteroid therapy for children admitted to the hospital with croup.<sup>34</sup> The Alberta Medical Association published a guideline for the diagnosis and management of croup in 2004, which was updated in 2007.<sup>4</sup> An algorithm for the management of croup in the outpatient setting is shown in Figure 1.

CONCLUSIONS  
AND RECOMMENDATIONS

Croup — both spasmodic croup and laryngotracheitis — is a common illness of early childhood that is frightening for both patients and their parents. For children such as the one described in the vignette, the standard of care is short-course corticosteroid therapy. This is most practically accomplished by the administration of a single dose of oral dexamethasone (0.6 mg per kilogram).<sup>4,8,49</sup> I would not recommend additional corticosteroid doses in children who do not have a response to this therapy, given the lack of data showing the efficacy of repeated doses and the potential risks associated with longer-term therapy. Depending on the severity of symptoms, children who do not have a response to dexamethasone should be evaluated in an emergency room or admitted to the hospital; further testing may be useful in such cases, including chest radiography for possible laryngotracheobronchitis or laryngotracheobronchopneumonia, as well as rapid influenza testing in the appropriate season. Children with severe symptoms should be treated with nebulized epinephrine (0.5 ml of 2.25% racemic epinephrine in 4.5 ml of normal saline or l-epinephrine diluted in 5 ml of normal saline at a ratio of 1:1000). If treatment is given in an outpatient setting, it should be followed by at least 2 hours of observation for a return of obstructive symptoms before discharge. Nebulized epinephrine treatments may need to be repeated many times in children with severe laryngotracheitis, but in many cases, this will prevent the need for endotracheal intubation.

If the evaluation suggests laryngotracheobronchitis or laryngotracheobronchopneumonia



**Figure 1. Management of Croup in Outpatients.**

Treatment guidelines are based on the severity of croup at the time of initial assessment. ICU denotes intensive care unit, LTB laryngotracheobronchitis, and LTBP laryngotracheobronchopneumonitis.

(i.e., an increased or low white-cell count with an increase in band forms, or radiographs showing pneumonia or soft densities within the trachea), treatment with antibiotics (e.g., vancomycin and cefotaxime) should be instituted, and in most instances, endotracheal intubation should be performed. In cases of severe croup occurring during documented epidemics caused by influ-

enza viruses, treatment with neuramidase inhibitors is appropriate.<sup>44</sup>

Dr. Cherry reports receiving consulting and lecture fees from Sanofi Pasteur and consulting fees from GlaxoSmithKline and MedImmune. No other potential conflict of interest relevant to this article was reported.

I thank Candice Bjornson and David Johnson, who supplied the case vignette, and Paul Krogstad, who offered helpful comments.

## REFERENCES

- Cherry JD. Croup. In: Kiple KF, ed. *The Cambridge world history of human disease*. New York: Cambridge University Press, 1993:654-7.
- Idem*. Croup (laryngitis, laryngotracheitis, spasmodic croup, laryngotracheobronchitis, bacterial tracheitis, and laryngotracheobronchopneumonitis). In: Feigin RD, Cherry JD, Demmler GJ, Kaplan S, eds. *Textbook of pediatric infectious diseases*. 5th ed. Philadelphia: W.B. Saunders, 2004:252-66.
- Davison FW. Acute obstructive laryngitis in children. *Penn Med J* 1950;53:250-4.
- Guideline for the diagnosis and management of croup. Alberta, ON, Canada: Alberta Medical Association, 2007. (Accessed December 28, 2007, at [http://www.topalbertadoctors.org/NR/rdonlyres/B072F5FE-1728-4BED-A88A-68A99341B98A/0/croup\\_guideline.pdf](http://www.topalbertadoctors.org/NR/rdonlyres/B072F5FE-1728-4BED-A88A-68A99341B98A/0/croup_guideline.pdf)).
- Cherry JD. State of the evidence for standard-of-care treatments for croup: are we where we need to be? *Pediatr Infect Dis J* 2005;24:Suppl:S198-S202.
- Idem*. Acute epiglottitis, laryngitis and croup. In: Remington JS, Swartz MN, eds. *Current clinical topics in infectious diseases*. New York: McGraw-Hill, 1981:1-30.
- Idem*. The treatment of croup: continued controversy due to failure of recognition of historic, ecologic, etiologic and clinical perspectives. *J Pediatr* 1979;94:352-4.
- Bjornson CL, Johnson DW. Croup — treatment update. *Pediatr Emerg Care* 2005;21:863-73.
- Denny FW, Murphy TF, Clyde WA Jr, Collier AM, Hendersen FW. Croup: an 11-year study in a pediatric practice. *Pediatrics* 1983;71:871-6.
- Segal AO, Crighton EJ, Moineddin R, Mamdani M, Upshur RE. Croup hospitalizations in Ontario: a 14-year time-series analysis. *Pediatrics* 2005;116:51-5.
- Davison FW. Acute laryngeal obstruction in children. *JAMA* 1959;171:1301-5.
- Szpunar J, Glowacki J, Laskowski A, Miszke A. Fibrinous laryngotracheobronchitis in children. *Arch Otolaryngol* 1971;93:173-8.
- Orton HB, Smith EL, Bell HO, Ford RA. Acute laryngotracheobronchitis: an analysis of sixty-two cases with report of autopsies in eight cases. *Arch Otolaryngol* 1941;33:926-60.
- Richards L. A further study of the pathology of acute laryngo-tracheobronchitis in children. *Ann Otol Rhinol Laryngol* 1938;47:326-41.
- Hopkins A, Lahiri T, Salerno R, Heath B. Changing epidemiology of life-threatening upper airway infections: the re-emergence of bacterial tracheitis. *Pediatrics* 2006;118:1418-21.
- Kasian GF, Bingham WT, Steinberg J, et al. Bacterial tracheitis in children. *CMAJ* 1989;140:46-50.
- Hall CB. Parainfluenza viruses. In: Feigin RD, Cherry JD, Demmler GJ, Kaplan S, eds. *Textbook of pediatric infectious diseases*. 5th ed. Philadelphia: W.B. Saunders, 2004:2270-83.
- Ottolini MG, Porter DD, Blanco JC, Prince GA. A cotton rat model of human parainfluenza 3 laryngotracheitis: virus growth, pathology, and therapy. *J Infect Dis* 2002;186:1713-7.
- Welliver RC, Sun M, Rinaldo D. Defective regulation of immune response in croup due to parainfluenza virus. *Pediatr Res* 1985;19:716-20.
- Welliver RC. Croup: continuing controversy. *Semin Pediatr Infect Dis* 1995;6:90-5.
- Dudin AA, Thalji A, Rambaud-Cousson A. Bacterial tracheitis among children hospitalized for severe obstructive dyspnea. *Pediatr Infect Dis J* 1990;9:293-5.
- Jones R, Santos JI, Overall JC. Bacterial tracheitis. *JAMA* 1979;242:721-6.
- Gardner HG, Powell KR, Roden VJ, Cherry JD. The evaluation of racemic epinephrine in the treatment of infectious croup. *Pediatrics* 1973;52:52-5.
- Westley CR, Cotton EK, Brooks JG. Nebulized racemic epinephrine by IPPB for the treatment of croup: a double-blind study. *Am J Dis Child* 1978;132:484-7.
- Fitzgerald DA. The assessment and management of croup. *Paediatr Respir Rev* 2006;7:73-81.
- Scolnik D, Coates AL, Stephens D, Da Silva Z, Lavine E, Schuh S. Controlled delivery of high vs low humidity vs mist therapy for croup in emergency departments: a randomized controlled trial. *JAMA* 2006;295:1274-80.
- Moore M, Little P. Humidified air inhalation for treating croup. *Cochrane Database Syst Rev* 2006;3:CD002870.
- Kairys SW, Olmstead EN, O'Connor GT. Steroid treatment of laryngotracheitis: a meta-analysis of the evidence from randomized trials. *Pediatrics* 1989;83:683-93.
- Ausejo M, Saenz A, Pham B, et al. The effectiveness of glucocorticoids in treating croup: meta-analysis. *BMJ* 1999;319:595-600.
- Russell K, Wiebe N, Saenz A, et al. Glucocorticoids for croup. *Cochrane Database Syst Rev* 2003;4:CD001955.
- Çetinkaya F, Tüfekçi BS, Kutluk G. A comparison of nebulized budesonide, and intramuscular, and oral dexamethasone for treatment of croup. *Int J Pediatr Otorhinolaryngol* 2004;68:453-6.
- Sparrow A, Geelhoed G. Prednisolone versus dexamethasone in croup: a randomized equivalence trial. *Arch Dis Child* 2006;91:580-3.
- Geelhoed GC. Budesonide offers no advantage when added to oral dexamethasone in the treatment of croup. *Pediatr Emerg Care* 2005;21:359-62.
- Canadian Paediatric Society. Steroid therapy for croup in children admitted to hospital. *CMAJ* 1992;147:429-32. [Erratum, *CMAJ* 1993;148:492.]
- Tenenbein M. The steroid odyssey in croup. *Pediatrics* 2005;116:230-1.
- Geelhoed GC. Sixteen years of croup in a Western Australian teaching hospital: effects of routine steroid treatment. *Ann Emerg Med* 1996;28:621-6.
- Taussig LM, Castro O, Beaudry PH, Fox WW, Bureau M. Treatment of laryngotracheobronchitis (croup): use of intermittent positive-pressure breathing and racemic epinephrine. *Am J Dis Child* 1975;129:790-3.
- Corneli HM, Bolte RG. Outpatient use of racemic epinephrine in croup. *Am Fam Physician* 1992;46:683-4.
- Kelley PB, Simon JE. Racemic epinephrine use in croup and disposition. *Am J Emerg Med* 1992;10:181-3.
- Prendergast M, Jones JS, Hartman D. Racemic epinephrine in the treatment of laryngotracheitis: can we identify children for outpatient therapy? *Am J Emerg Med* 1994;12:613-6.
- Fogel JM, Berg IJ, Gerber MA, Sherter

- CB. Racemic epinephrine in the treatment of croup: nebulization alone versus nebulization with intermittent positive pressure breathing. *J Pediatr* 1982;101:1028-31.
42. Waisman Y, Klein BL, Boenning DA, et al. Prospective randomized double-blind study comparing L-epinephrine and racemic epinephrine aerosols in the treatment of laryngotracheitis (croup). *Pediatrics* 1992;89:302-6.
43. Weber JE, Chudnofsky CR, Younger JG, et al. A randomized comparison of helium-oxygen mixture (Heliox) and racemic epinephrine for the treatment of moderate to severe croup. *Pediatrics* 2001; 107(6):E96.
44. Prevention and control of influenza: recommendations of the Advisory Committee on Immunization Practices (ACIP). *MMWR Recomm Rep* 2006;55:RR-10:1-42. [Erratum, *MMWR Morb Mortal Wkly Rep* 2006;55:800.]
45. Super DM, Cartelli NA, Brooks LJ, Lembo RM, Kumar ML. A prospective randomized double-blind study to evaluate the effect of dexamethasone in acute laryngotracheitis. *J Pediatr* 1989;115:323-9.
46. Johnson DW, Schuh S, Koren G, Jaffee DM. Outpatient treatment of croup with nebulized dexamethasone. *Arch Pediatr Adolesc Med* 1996;150:349-55.
47. Burton DM, Seid AB, Kearns DB, Pransky SM. *Candida* laryngotracheitis: a complication of combined steroid and antibiotic usage in croup. *Int J Pediatr Otorhinolaryngol* 1992;23:171-5.
48. Myers C, Corbelli R, Schrenzel J, Gervaix A. Multiple pulmonary abscesses caused by *Legionella pneumophila* infection in an infant with croup. *Pediatr Infect Dis J* 2006;25:753-4.
49. Bjornson CL, Klassen TP, Williamson J, et al. A randomized trial of a single dose of oral dexamethasone for mild croup. *N Engl J Med* 2004;351:1306-13.

Copyright © 2008 Massachusetts Medical Society.

#### IMAGES IN CLINICAL MEDICINE

The *Journal* welcomes consideration of new submissions for Images in Clinical Medicine. Instructions for authors and procedures for submissions can be found on the *Journal's* Web site at [www.nejm.org](http://www.nejm.org). At the discretion of the editor, images that are accepted for publication may appear in the print version of the *Journal*, the electronic version, or both.