Foot and ankle

Objectives

- Review relevant anatomy of the foot and ankle
- Learn the approach to examining the foot and ankle
- Learn the basics of diagnosis and treatment of ankle sprains
- Overview of other common causes of ankle and foot pain in athletes

Anatomy

- Bone

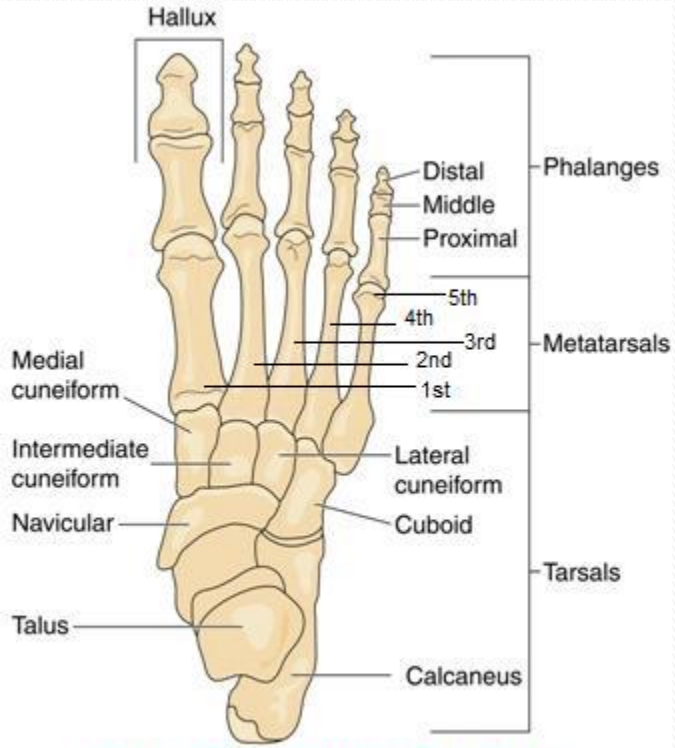

BONES OF THE FOOT (FROM ABOVE)

Anatomy

- Ligaments

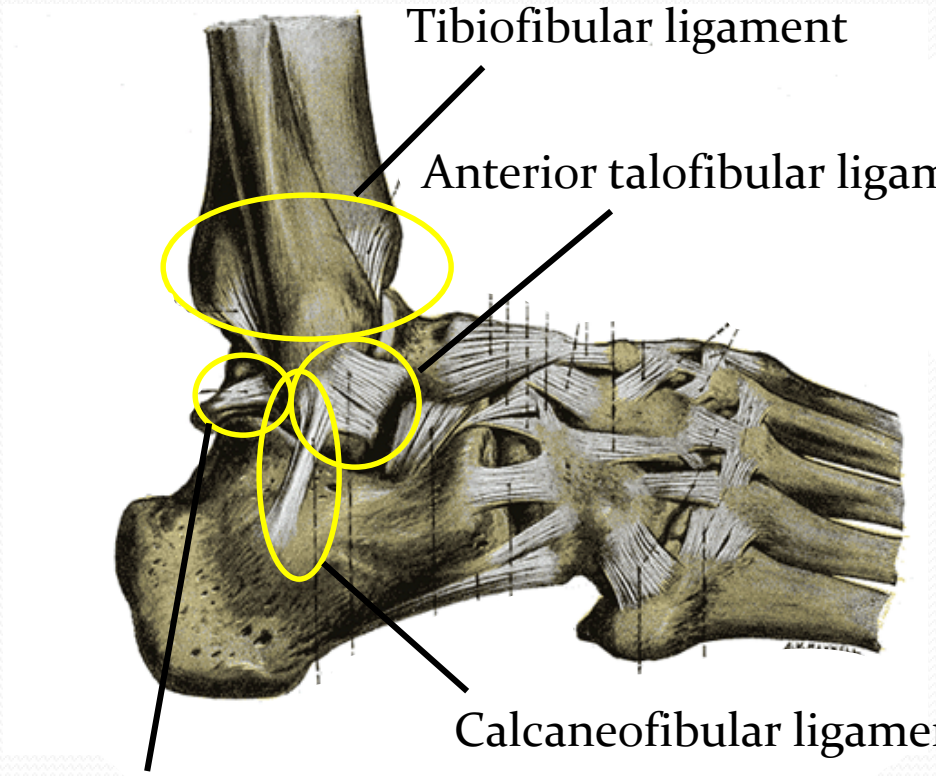

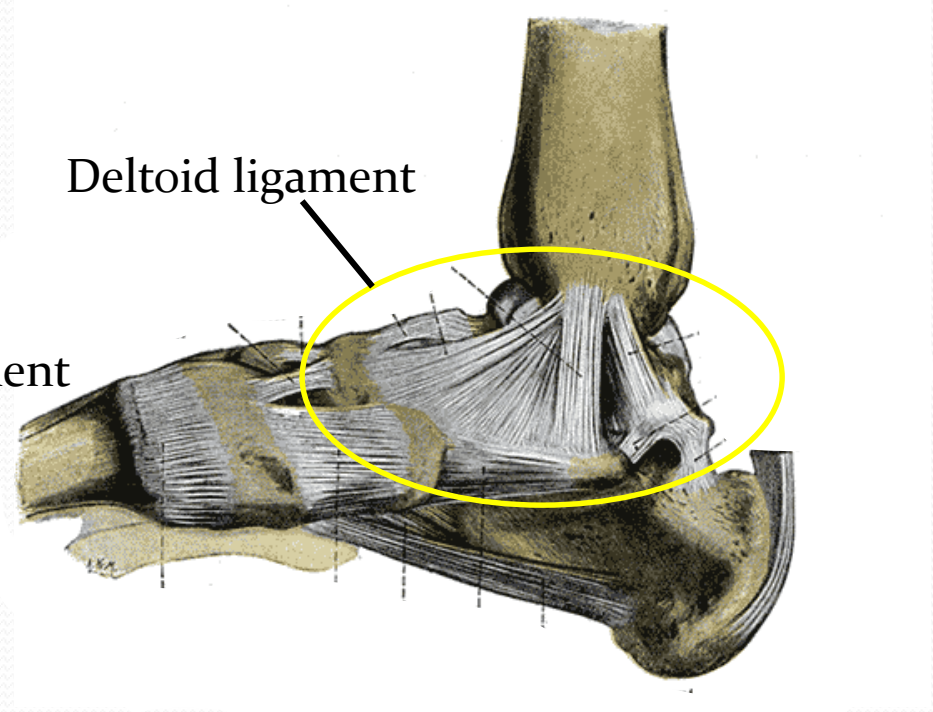

Anatomy

- Muscles

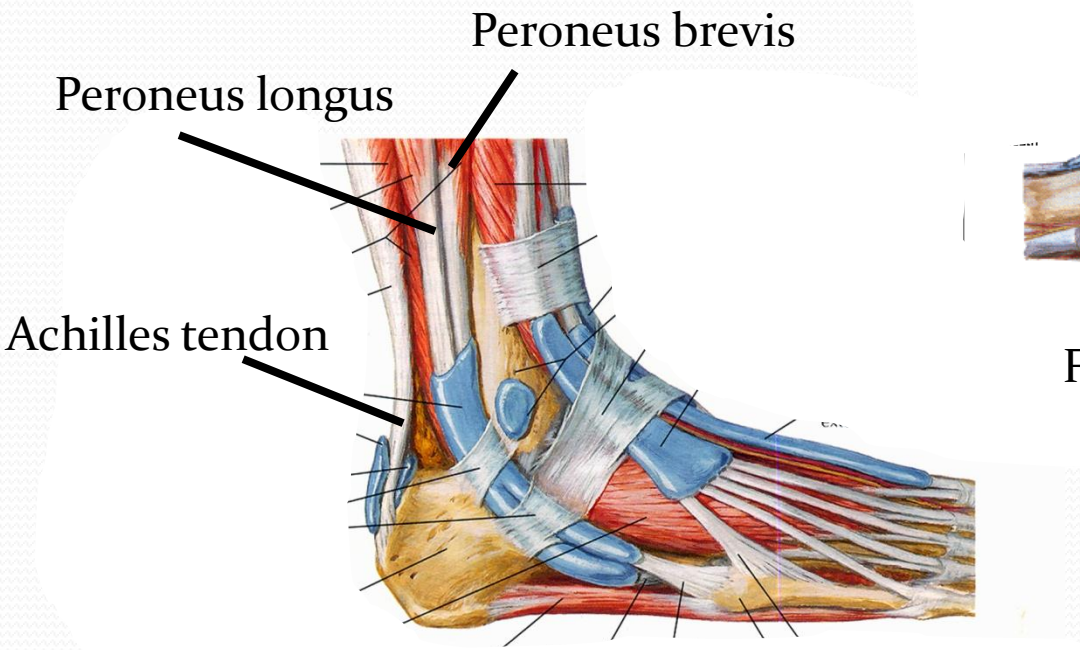

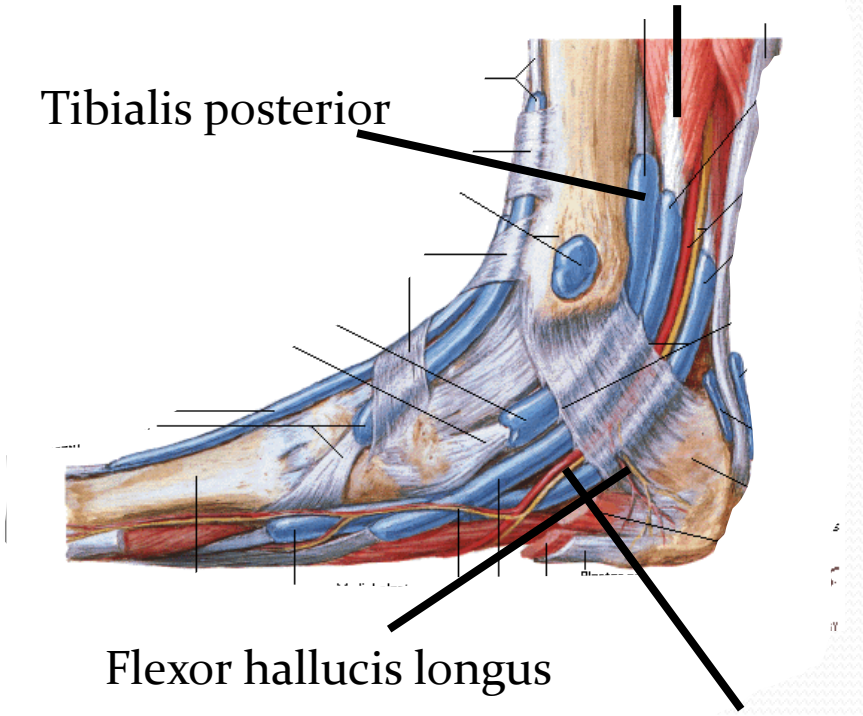

Exam

- Inspection
- Palpation
- ROM
  - Active
  - Passive
  - Resisted
- Provocative tests
- Functional tests

Exam

- Inspection:
  - Laceration, blisters, toe nails, swelling, bruising, deformity

Exam

- Palpation

Exam

- ROM:
  - Dorsiflexion, plantarflexion, inversion, eversion

Exam

- Provocative tests
  - Anterior drawer; stability of anterior talofibular ligament

https://www.youtube.com/watch?v=eiyDAIGPZCU

Exam

- Provacative test
  - Inversion stress test; stability of calcaneofibular ligament

Exam

- Provacative tests
  - Syndesmosis squeeze; tibiofibular ligament

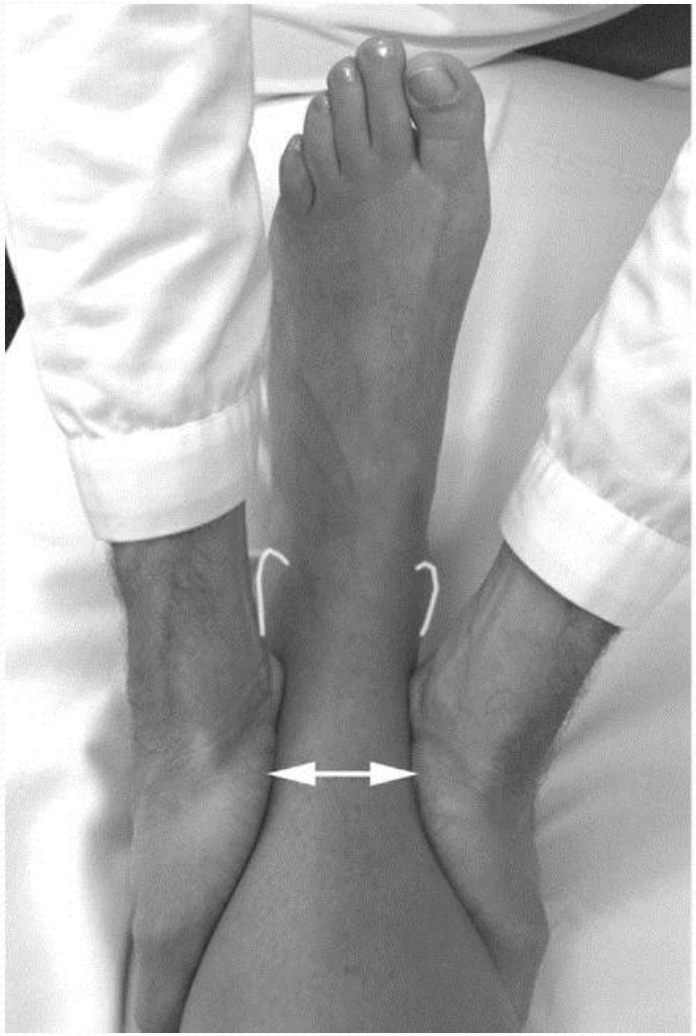

Exam

- Functional tests
  - Gait, single leg raise, 5 hop test

Ankle Sprain

- Most common sports injury; usually inversion
- Graded 1-3 based on severity
- Recovery 1-10 weeks

Ottawa Ankle Rules

- Inability to bear weight
- Tenderness over medial or lateral malleolus or 6 cm above
- Pain over the navicular or 5th metatarsal

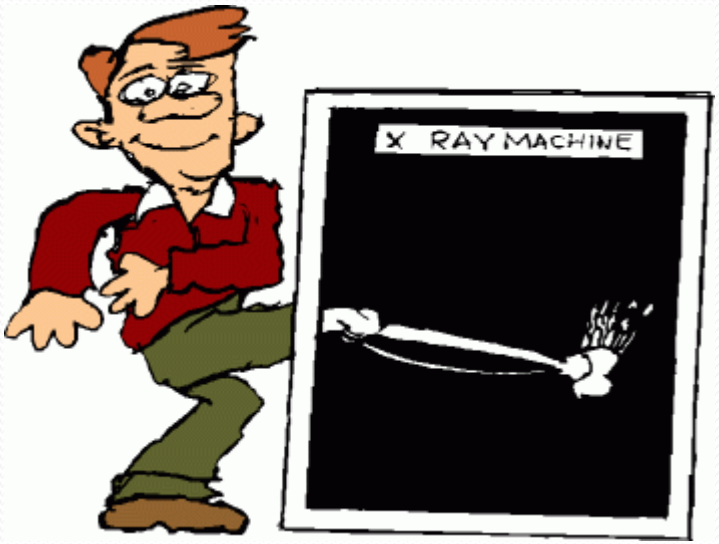

Treatment

- P-Protection
- R-Relative Rest
- I-Ice
- C-Compression
- E-Elevation
- M-Medication
- M-Modalities
- M-Motion
- S-Strength

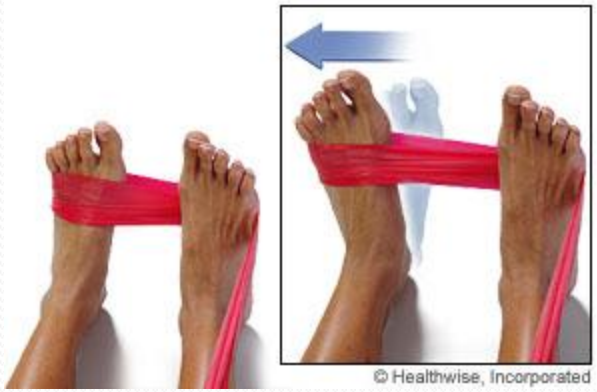

High ankle sprain

- Tear of the tibiofibular ligaments
- Positive squeeze test
- Takes about twice as long to recover

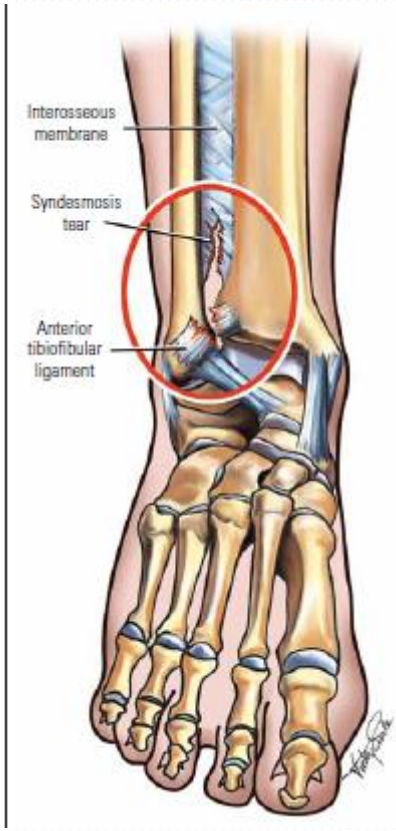

Peroneal Tendonitis

- Peroneus longus and brevis are evertors and dorsiflexors
- Causes: recurrent inversion injury, excessive pronation, tight plantarflexors
- Tenderness around lateral malleolus
- Pain with inversion and resisted eversion
- May have tight calf or stiff foot
- Can sublux

5th Metatarsal Fracture

- Avulsion fracture
  - Inversion injury
  - Pull of peroneus brevis
  - Heal well with immobilization

5th Metatarsal Fracture

- Diaphyseal Fracture
  - Acute vs. chronic/stress
  - High risk for malunion
  - Treatment:
    - For acute injury; immobilization for 6-8 wks
    - For malunion injury; screw fixation with bone graft

Sever's disease

- Calcaneal apophysitis
  - Heal pain in skeletally immature athletes
  - Pain with activity
  - Tenderness over Achilles tendon insertion
  - Associated with tight calf muscles/limited dorsiflexion

Turf Toe

- Sprain of first MTP
- Result of forced hyperextension against a stiff surface
- Pain and swelling at first MTP joint
- Exam: tenderness over the joint, dorsal tenderness suggests more severe injury, painful ROM
- Treatment: pain control, taping for protection, stiff-soled shoe or boot

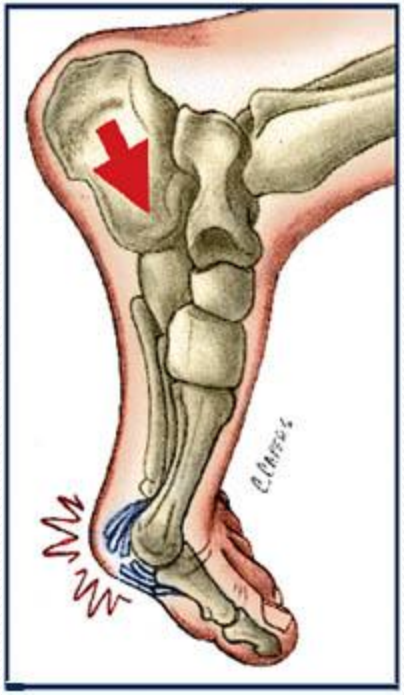

Plantar fasciitis

- Risk factors: pes planus or pes cavus, excessive pronation, obesity
- Pain worse in the morning
- Tenderness over heel and fascia
- Treatments: calf stretching, ice massage, heel cups, supportive footwear, night splint

Questions

- The 14-year-old star of the high school cross country team has had right foot pain for 3 weeks. The pain became more severe during practice last night, and it is now persistent with weight bearing. Examination shows mild swelling over the third metatarsal with point tenderness. Sensation and perfusion are normal. Radiographs show no significant abnormalities. Of the following, the MOST appropriate recommendation for this patient is…

- ibuprofen pretreatment and foot taping before practice
- immediate return to activity without restriction
- magnetic resonance imaging of foot with no participation pending results
- repeat the radiographs in 5 days; if there are no further signs of bony disruption, the patient may return to full participation
- rest for 2 weeks followed by a gradual return to full participation

- The adolescent in the vignette shows evidence of a stress injury related to sports participation. These injuries occur when repetitive stress is applied to bone and produces microfractures. With inadequate time for bone repair, microfractures can lead to a stress reaction and ultimately a stress fracture.
- Increasing pain, particularly with weight bearing, is a signal that a stress fracture has occurred.
- While radiographs should be obtained in this setting, they often do not show the fracture immediately. Plain radiographs typically become abnormal 2 to 4 weeks after symptoms increase, showing a faint lucency in the involved bone, periosteal thickening or sclerosis, cortical changes, or callus formation.
- To obtain a definitive diagnosis, magnetic resonance imaging (MRI) is indicated. MRI is sensitive and specific for stress injury and can eliminate other potential diagnoses, such as soft tissue infections.
- Potential long-term consequences of stress fractures include avascular necrosis of the involved bone and recurrent.

Questions

- Amy is a 14 yo female soccer player. She took a funny step while running for the ball in a game yesterday and hurt her ankle. Today, she has swelling and mild bruising over her L lateral ankle. She is tender around the lateral malleolus. Which ligament is the most likely injured?
- Anterior talofibular ligament
- Deltoid ligamnet
- Posterior talofibular ligament
- Tibiofibular ligament

Questions

- An 18 yo defensive lineman in football comes in with an injury following a football game the night before. He is not sure what happened as the play ended with a pile up, but he felt pain in his ankle when he got up to go back to the huddle. His ankle is very swollen and bruised. He is most tender over the anterior ankle and his squeeze test is positive. Which of the following is true regarding his injury:
- He most likely has a high ankle sprain
- An x-ray is necessary for diagnosis
- He should heal more quickly than a regular ankle sprain
- He injured his calcaneofibular ligament