

# Dental Trauma

NOV. 4, 2011

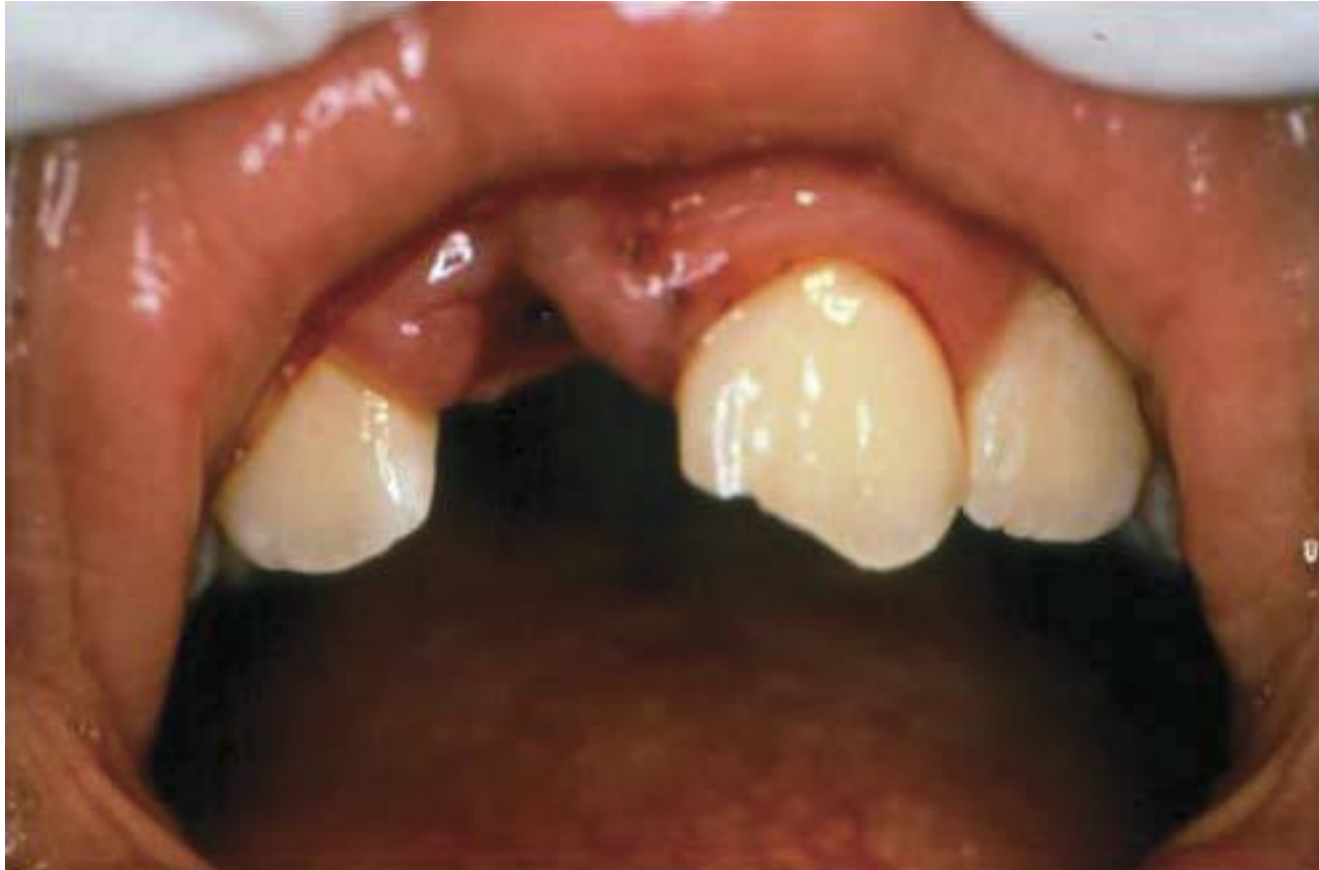Nita Davis

PGY1

# Question 1

- ▶ A 12 year old boy got punched in the face during a boxing match. He began to bleed from the mouth. He then realized that one of his front incisors was knocked out and was lying on the mat. Which of these is TRUE:
  - a) An avulsed permanent teeth should be reimplanted into the socket ideally within 2 hours if not stored
  - b) The best storage solution for an avulsed tooth is cold water
  - c) An avulsed primary teeth may be reimplanted
  - d) Readily available storage solution for an avulsed tooth include milk or saliva
  - e) An avulsed tooth should never be reimplanted except by a trained medical personnel

# Question 1

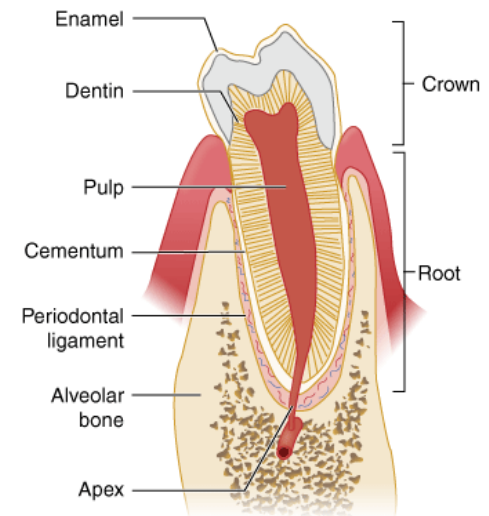


# Answer 1

- ▶ A 12 year old boy got punched in the face during a boxing match. He began to bleed from the mouth. He then realized that one of his front incisors was knocked out and was lying on the mat. Which of these is TRUE:
  - a) An avulsed permanent teeth should be reimplanted into the socket ideally within 2 hours if not stored
  - b) The best storage solution for an avulsed tooth is cold water
  - c) An avulsed primary teeth may be reimplanted
  - d) **Readily available storage solution for an avulsed tooth include milk or saliva**
  - e) An avulsed tooth should never be reimplanted except by a trained medical personnel

# Anatomy of the Tooth

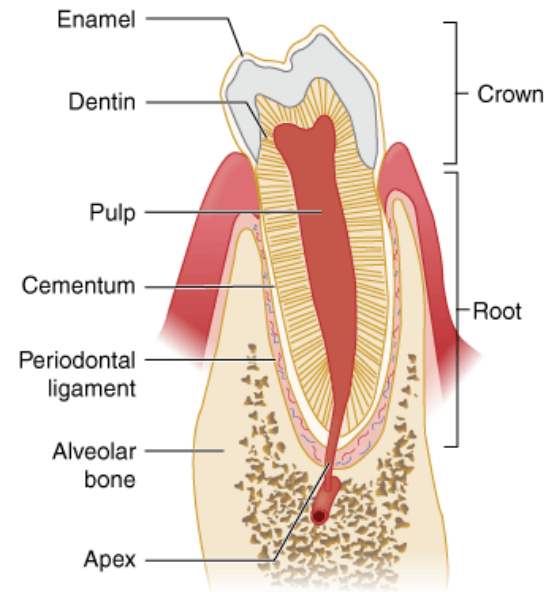
- ▶ A tooth consists largely of *dentin*, which surrounds the *pulp* (neurovascular supply of the tooth)
- ▶ Dentin is a homogeneous material produced by pulpal odontoblasts throughout life.



Source: Tintinalli JE, Stapczynski JS, Ma OJ, Cline DM, Cydulka RK, Meckler GD: *Tintinalli's Emergency Medicine: A Comprehensive Study Guide, 7th Edition*: <http://www.accessmedicine.com>  
Copyright © The McGraw-Hill Companies, Inc. All rights reserved.

# Anatomy of the Tooth

- ▶ The  *crown*, or the visible portion of tooth, consists of a thick  *enamel* layer overlying the dentin.
- ▶ The  *root* portion of the tooth extends into the alveolar bone and is covered with a thin layer of  *cementum*.



Source: Tintinalli JE, Stapczynski JS, Ma OJ, Cline DM, Cydulka RK, Meckler GD: *Tintinalli's Emergency Medicine: A Comprehensive Study Guide, 7th Edition*; <http://www.accessmedicine.com>  
Copyright © The McGraw-Hill Companies, Inc. All rights reserved.

# Avulsion of Tooth

- ▶ Avulsion of the tooth includes the complete displacement from the alveolar ridge; the periodontal ligament is severed, and fracture of the alveolus may occur.
- ▶ It is a true dental emergency.
- ▶ Reimplantation of tooth should be done by the first capable person (eg. The injured child, a parent, teacher, coach or PCP)
- ▶ The survival of the avulsed tooth is inversely related to the amount of time spent out of the oral cavity

# Avulsion of Tooth

- ▶ Management of the injury focuses on maintaining the vitality of the periodontal ligament.
- ▶ The tooth should be ideally implanted within **15 minutes** and up to an hour if stored properly



# Avulsion of Tooth

- ▶ Cold milk is a readily available and relatively aseptic storage medium.
  - It's osmolality makes it conducive to maintaining the vitality of periodontal ligaments.
- ▶ The patient's own saliva is an alternative to milk
- ▶ Tap water has a low osmolality which will cause cells to swell and rupture within minutes.

# Avulsion of Tooth

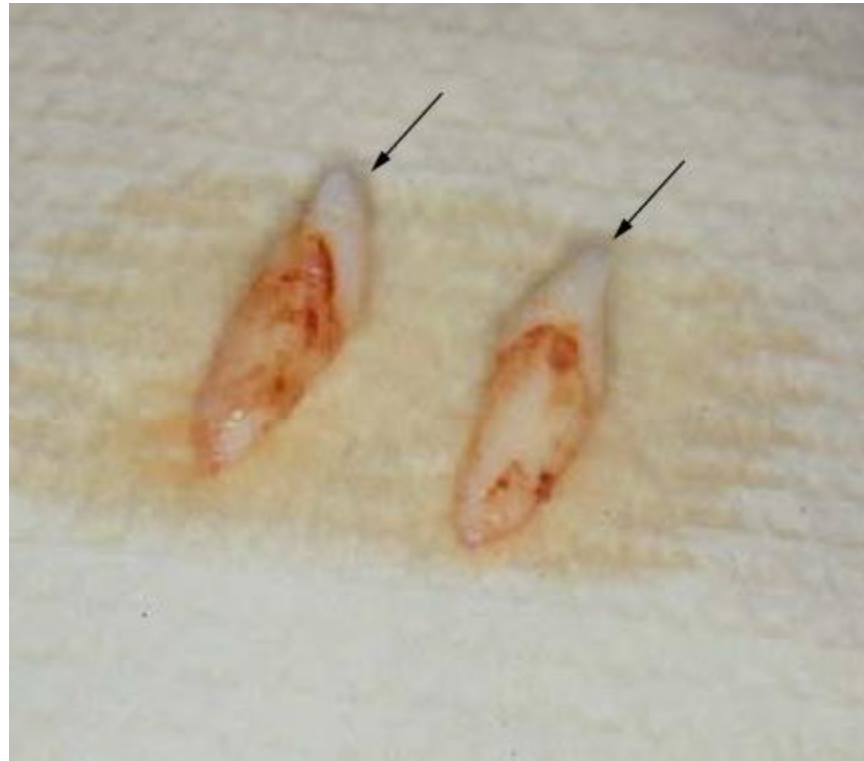- ▶ Avulsed primary tooth should *never* be replanted because of the potential damage to the developing tooth bud.
- ▶ Tetanus prophylaxis may be indicated if vaccines not up-to-date

# Avulsion of Tooth

Reimplantation procedure:

- ▶ Tooth should be handled with care by the crown to prevent damage of periodontal ligament
- ▶ Debris should be removed by gently rinsing with saline or tap water; do not scrub the tooth
- ▶ The tooth is then manually reimpanted into the socket
- ▶ The tooth is kept in place by the child through finger pressure or by biting on a guaze pad or clean towel
- ▶ Follow up with a pediatric dentist as soon as possible

# Avulsion of Tooth



Evaluation and management of dental injuries in children  
Dennis J McTigue, DDS  
[www.uptodate.com](http://www.uptodate.com)

# Question 2

- ▶ 10 year old boy is riding in his driveway on his new bike. He falls of the bike and begins to cry. His father notes that a piece of one of central maxillary incisors is lying in the driveway. Which of these is TRUE:
  - a) He should store the tooth fragment in milk to keep viable cells alive
  - b) Crown fragments ideally should be reattached within 7 days
  - c) The level of inflammation and necrosis of the pulp is not a major determining factor in reattachment of the fragment
  - d) Storage of the fragment in tap water WILL NOT prevent discoloration
  - e) There is NO cosmetic benefit in reattaching the tooth fragment

# Answer 2

- ▶ 10 year old boy is riding in his driveway on his new bike. He falls of the bike and begins to cry. His father notes that a piece of one of central maxillary incisors is lying in the driveway. Which of these is TRUE:
  - a) He should store the tooth fragment in milk to keep viable cells alive
  - b) **Crown fragments ideally should be reattached within 7 days**
  - c) The level of inflammation and necrosis of the pulp is not a major determining factor in reattachment of the fragment
  - d) Storage of the fragment in tap water WILL NOT prevent discoloration
  - e) There is NO cosmetic benefit in reattaching the tooth fragment

# Fracture of Tooth

- ▶ Most fractures of the permanent teeth, even those with exposure of pulp, can be treated successfully hours after the injury, depending upon the level of inflammation and necrosis of the pulp
- ▶ The child should be referred to a dentist as soon as possible, ideally within seven days, to optimize comfort and functional and cosmetic outcomes

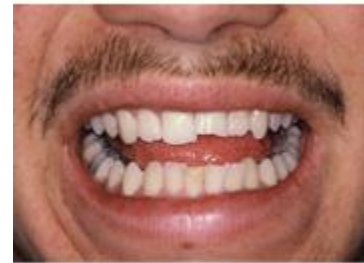# Fracture of Tooth

- ▶ Tooth fragments from crown fractures can be reattached if they are retrieved and kept properly hydrated
- ▶ Special solutions are not necessary because they have no fibroblasts to keep viable
- ▶ The fragment should be kept hydrated in tap water because discoloration occurs with desiccation.



# Fracture of Tooth

- ▶ The fractured tooth can be restored with composite resin materials if the fragment is not retrieved



Tintinalli's Emergency Medicine:  
A Comprehensive Study Guide, 7e

# References

- ▶ Evaluation and management of dental injuries in children, Dennis J McTigue, DDS, [www.uptodate.com](http://www.uptodate.com)
- ▶ Kids with dental trauma often present to medical offices, Jessica Y. Lee, *AAP News 2008;29;17*
- ▶ Tintinalli's Emergency Medicine: A Comprehensive Study Guide, 7e , Judith E. Tintinalli, J. Stephan Stapczynski, David M. Cline, O. John Ma, Rita K. Cydulka, and Garth D. Meckler  
The American College of Emergency Physicians