

PEDIATRICS®

OFFICIAL JOURNAL OF THE AMERICAN ACADEMY OF PEDIATRICS

Headache in Young Children in the Emergency Department: Use of Computed Tomography

Tarannum M. Lateef, Mandeep Grewal, William McClintock, James Chamberlain, Himanshu Kaulas and Karin B. Nelson

Pediatrics 2009;124:e12-e17

DOI: 10.1542/peds.2008-3150

The online version of this article, along with updated information and services, is located on the World Wide Web at:

<http://www.pediatrics.org/cgi/content/full/124/1/e12>

PEDIATRICS is the official journal of the American Academy of Pediatrics. A monthly publication, it has been published continuously since 1948. PEDIATRICS is owned, published, and trademarked by the American Academy of Pediatrics, 141 Northwest Point Boulevard, Elk Grove Village, Illinois, 60007. Copyright © 2009 by the American Academy of Pediatrics. All rights reserved. Print ISSN: 0031-4005. Online ISSN: 1098-4275.

American Academy of Pediatrics

DEDICATED TO THE HEALTH OF ALL CHILDREN™



Headache in Young Children in the Emergency Department: Use of Computed Tomography



WHAT'S KNOWN ON THIS SUBJECT: Neuroimaging because of recurrent childhood headaches has limited value; especially in the setting of normal physical examination. The risk of radiation exposure from CT scans is highest in the youngest age group.



WHAT THIS STUDY ADDS: This study addresses the diagnostic utility of CT scans, in an ED setting, for children <6 years of age.

abstract

OBJECTIVE: The goal was to determine whether computed tomographic (CT) scans led to better acute care of young children with headache presenting the emergency department (ED).

METHODS: We examined the records of 364 children 2 to 5 years of age who presented with headache to a large urban ED between July 1, 2003, and June 30, 2006. By reviewing initial history and examination findings, we first identified patients with secondary headaches (ie, with readily identifiable explanations such as ventriculoperitoneal shunts, known brain tumors, or acute illnesses, such as viral syndromes, fever, probable meningitis, or trauma). Charts for the remaining patients were reviewed for headache history, neurologic examination findings, laboratory and neuroimaging results, final diagnosis, and disposition.

RESULTS: On the basis of initial history and physical examination results, 306 children (84%) had secondary headaches. For 72% of those children, acute febrile illnesses and viral respiratory syndromes accounted for the headaches. Among the 58 children (16%) who had no recognized central nervous system disease or systemic illness at presentation, 28% had CT scans performed. Of those, 1 scan yielded abnormal results, showing a brainstem glioma; the patient demonstrated abnormal neurologic examination findings on the day of presentation. For 15 (94%) of 16 patients, the CT scans did not contribute to diagnosis or management. For 59% of children with apparently primary headaches, no family history was recorded.

CONCLUSION: For young children presenting to the ED with headache but normal neurologic examination findings and nonworrying history, CT scans seldom lead to diagnosis or contribute to immediate management. *Pediatrics* 2009;124:e12–e17

CONTRIBUTORS: Tarannum M. Lateef, MD,^a Mandeep Grewal, BS,^a William McClintock, MD,^a James Chamberlain, MD,^b Himanshu Kaulas, MBBS,^a and Karin B. Nelson, MD^{a,c}

Departments of ^aNeurology and ^bEmergency Medicine, Children's National Medical Center and George Washington University School of Medicine, Washington, DC; and ^cNational Institute of Neurological Disorders and Stroke, National Institutes of Health, Bethesda, Maryland

KEY WORDS

headache, child, emergency department, computed tomography

ABBREVIATIONS

ED—emergency department

CT—computed tomographic

The content of this publication does not necessarily reflect the views or policies of the Department of Health and Human Services, and mention of trade names, commercial products, or organizations does not imply endorsement by the US government.

www.pediatrics.org/cgi/doi/10.1542/peds.2008-3150

doi:10.1542/peds.2008-3150

Accepted for publication Feb 20, 2009

Address correspondence to Tarannum M. Lateef, MD, Department of Neurology, Children's National Medical Center, 111 Michigan Ave, Washington, DC 20010. E-mail: tlateef@cnmc.org

PEDIATRICS (ISSN Numbers: Print, 0031-4005; Online, 1098-4275).

Copyright © 2009 by the American Academy of Pediatrics

FINANCIAL DISCLOSURE: *The authors have indicated they have no financial relationships relevant to this article to disclose.*

Headache is a common complaint, even in early childhood. When children with headache present to the emergency department (ED), they often are accompanied by anxious parents who are fearful of an ominous cause for their child's headache. ED physicians have the challenging role of reassuring parents, when appropriate, while working in a setting where a detailed headache history, a thorough physical examination, and knowledge of familial factors are less readily available than in office-based practice. Studies investigating the cause of headaches presenting to pediatric EDs showed that most such visits are attributable to common nonominous conditions, such as upper respiratory illnesses or migraine.¹⁻⁵ None of those studies distinguished causes on the basis of age or formally examined the utility of computed tomographic (CT) scans for young children in the ED setting.

The prevalence of any type of headache ranges from 37% to 51% for 7-year-old children, gradually increasing to 57% to 82% by 15 years of age.⁶⁻¹⁰ Most pediatric headaches not occurring in the context of a febrile illness or trauma, even in children <6 years of age, are primary headaches such as migraine or tension headaches. However, migraine headaches in this age group may not meet the usual diagnostic criteria. Furthermore, "dangerous" headaches may be more common in this population.¹¹ The latter group includes possibilities such as brain tumors, meningitis, venous sinus thrombosis, subarachnoid hemorrhage, and other disorders requiring prompt specific management. The diagnostic approach to pediatric headache in very young children is thus of great importance.

The American Academy of Neurology practice parameter of 2002 addresses only children with recurrent headaches, does not discuss whether its

recommendations are altered by the age of the child, and makes no specific recommendations about patients in the ED setting.¹² Although CT scans are readily available and are used frequently in EDs, they are expensive, pose a nontrivial risk of radiation exposure for children,¹³⁻¹⁵ and have shown limited value in the evaluation of nonemergency pediatric headaches in cases with normal neurologic examination findings.¹⁶⁻²⁰ The objectives of this study were to describe our clinical experience with headache in a busy urban pediatric ED and to determine whether CT scans for young children with headache led to better ED management, justifying the risk of radiation for the children.

METHODS

The ED records for children 2 through 5 years of age who presented to the Children's National Medical Center ED between July 1, 2003, and June 30, 2006, with headache as their chief complaint were accessed by using a computerized billing and data entry system. Search words for diagnosis or chief complaint included "headache," "migraine," and "cephalalgia." The search yielded a total of 364 patients. The Children's National Medical Center is both a primary care facility for the local population and a referral facility for a much larger metropolitan area.

By reviewing initial history and examination findings, we first identified patients with known preexisting pathologic conditions, such as ventriculoperitoneal shunts or brain tumors, and those with acute illnesses, such as viral syndromes, fever, probable meningitis, or trauma. These patients were counted and the causes of their secondary headaches were noted. The charts for the remaining patients were reviewed for headache history, previous evaluation, family and social history, and physical exam-

ination findings. General physical examination parameters were noted, including vital signs at presentation. Neurologic examination abnormalities, when found, were assigned to 1 of the following categories: mental status, language, cranial nerves, motor, sensory, cerebellar, gait, or reflexes. These initial data were then examined for the presence of possible "red flags" in either the history or physical examination, such as chronic progressive pattern, acute onset of the worst headache of the patient's life, focal neurologic symptoms, or headaches or emesis on awakening. After an initial clinical impression was recorded, the results of laboratory studies and CT scans, when performed, were examined. Finally, we ascertained a final diagnostic impression and disposition for all patients. Follow-up assessment was attempted by searching for records of clinic visits after ED discharge.

ED records were accessed through an electronic database and were recorded in a set of forms specially designed with queries for this study. Data management and analysis were accomplished by creating a Children's Hospital Research Information System database. The statistical software used was Stata 10 (Stata, College Station, TX). Fisher's exact test and χ^2 tests were used in the final analyses.

RESULTS

The Children's National Medical Center ED evaluated a total of 3092 patients with headache between the ages of 2 and 18 years. ED records for 364 children, 2 through 5 years of age, were analyzed (Fig 1). For 306 children (84%), secondary headaches were thought to be present, on the basis of initial history and physical examination findings documenting a recognizable illness (often infectious) considered to be the underlying problem. An

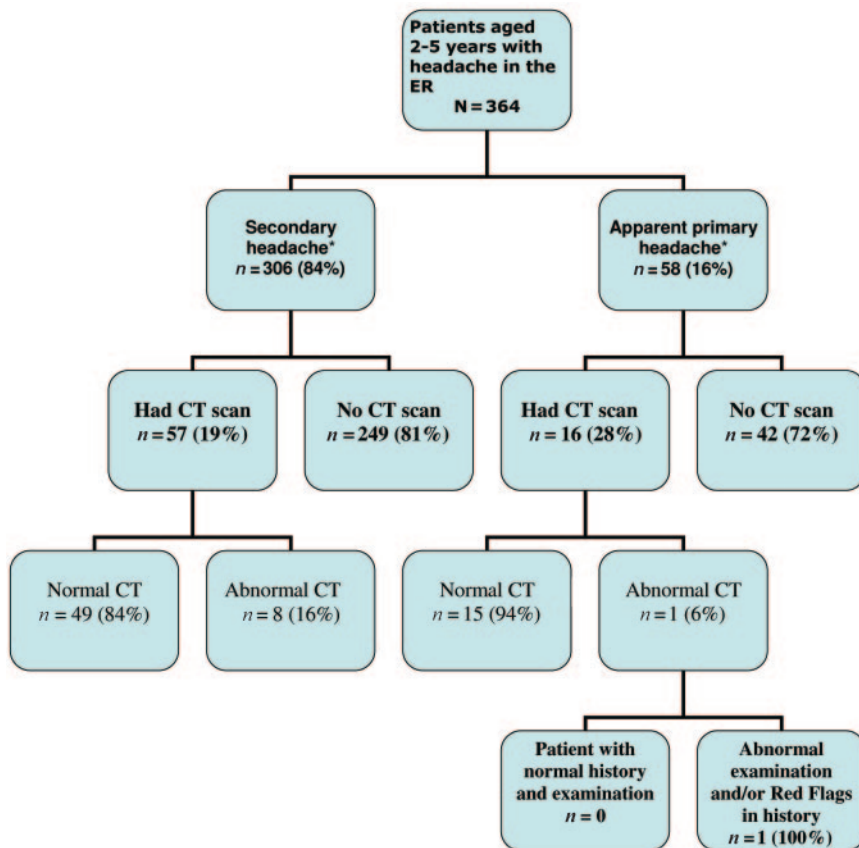


FIGURE 1

Experience with CT scans in the evaluation of headache in the pediatric ED. Only 1 child who did not have an infectious illness or recognized brain disease at presentation had abnormal CT scan results, and that child had worrisome history findings and abnormal neurologic examination findings on the day of presentation. *Initial study impression based on presenting history findings, without knowledge of CT scan results or even whether a scan had been ordered.

additional subgroup had known neurologic disorders (brain tumors, neurocutaneous syndromes, neurodegenerative diseases, or neurometabolic diseases) or previously established systemic diseases (congenital heart problems, malignancy, coagulopathy, rheumatologic diseases, or collagen vascular disease). The remaining 58 children (16%) had no recognized brain disease or systemic illness at presentation.

Among the 58 children who had no recognized neurologic or systemic disease before presentation, 16 (28%) underwent CT scanning. One child's CT scan yielded abnormal results, showing a brainstem glioma. The child was a 5-year-old boy with a history of wors-

ening headaches over the past 5 days and significant pain on awakening, sometimes accompanied by emesis. Noting the escalating intensity of symptoms, the ED physician ordered a head CT scan, documenting a concern regarding "increased intracranial pressure." This patient had abnormal neurologic examination findings, that is, vertical nystagmus documented by the neurosurgeon (but not by ED personnel), on the day of presentation to the ED. For 15 (94%) of the 16 children who underwent CT scanning, the results were normal. The final diagnostic impression was not altered significantly by the addition of the CT scans ($P = .26$). Therefore, in this study, CT scans did not contribute significantly

to the detection of intracranial pathologic conditions not suspected in the initial clinical evaluations.

We further analyzed ED records for the 58 children who had no recognizable central nervous system or systemic disorder at presentation, to determine whether the 16 children (28%) who underwent CT scanning could be readily distinguished from the 42 (72%) who did not. Factors such as the age of the child, physical and neurologic examination findings, and vital signs were compared. Among the 16 children who underwent imaging, 1 had worsening headache, emesis, and abnormal neurologic examination results. This child was found to have a brainstem glioma, as described above. Fifty-seven children, including those who underwent imaging and those who did not, had normal examination results. The mean age of the children who underwent CT scanning was 4.1 years (range: 2.1–5.9 years), and the mean age of the children who did not was 4.9 years (range: 2.6–5.9 years). Among the 16 children who underwent CT scanning, 3 (19%) were ≤ 3 years of age; among the 42 children who did not undergo CT scanning, 5 (12%) were ≤ 3 years of age. Reasons for scanning, when documented as such in the chart, included recent sinusitis for 1 child, "new" headaches for 2 children, "posterior" location of headache for 1 child, and "eye-rolling spells" (presumably concerning with respect to seizures) for 1 child.

At the time of discharge from the ED, 57 patients had a final diagnostic impression of apparently primary headache; 5 of them received a diagnosis of migraine. The remaining patients did not have sufficient history findings documented by ED personnel to permit further categorization of their primary headache subtype. Patients with a final diagnosis of secondary headaches totaled 307. Table 1 presents the causes

TABLE 1 Causes of Headache in Young Children in the Pediatric ED

Diagnoses	n (%)
Primary headaches ^a	57 (15.7)
Migraine	5 (8.7)
Primary headache, unclassified	52 (91.3)
Secondary headaches ^a	307 (84.3)
Neurologic	
Trauma	47 (15.3)
Ventriculoperitoneal shunt	14 (4.5)
Seizures	2 (0.7)
Brain tumor	
Known	6 (2.0)
Newly diagnosed ^b	1 (0.3)
Meningitis	4 (1.3)
Other ^c	2 (0.7)
Nonneurologic	
Viral/respiratory/febrile illness	222 (72.3)
Chronic systemic disease	4 (1.3)
Other ^d	5 (1.6)
Total	364 (100)

^a Established on the basis of the final diagnostic impressions and review of the results of CT scanning (if performed).

^b The patient with a newly diagnosed brain tumor was initially in the “apparently primary” group (Fig 1). Although this patient did not have a previous diagnosis of central nervous system disease, there were suggestive history findings and abnormal neurologic examination results on the day of presentation (see text).

^c Stroke or acute demyelinating encephalomyelitis.

^d Contact dermatitis of the scalp, corneal abrasion, retropharyngeal abscess, dental pain, or lymphadenitis.

of headache on the basis of the final diagnostic impressions.

Among the children for whom the initial diagnosis was not certain, many charts (59%) did not include family history, an element of the evaluation that can contribute importantly to the diagnosis for a young child with headache. Headache history was documented for 16 (28%) of 58 patients with apparent primary headache. Of those 16 patients, 4 reported never having headaches previously, 7 reported having headaches sometimes, and 5 confirmed having headaches often.

Follow-up information within the Children’s National Medical Center medical system was available for 43 (75%) of 57 patients without further diagnosis of headache type at ED discharge. Of those 43 patients, 5 were subsequently seen in the neurology clinic, where 3 were diagnosed as having mi-

graine, 1 headache not otherwise specified, and 1 cyclic vomiting syndrome. The average time between the ED visit for headache and the last follow-up visit at Children’s National Medical Center was 28 months (range: 1–59 months). Although most of the follow-up care occurred in subspecialty clinics other than neurology, none of the follow-up records documented the occurrence of a previously undetected neurologic cause for headaches.

DISCUSSION

We addressed the question of benefit versus risk from head CT scans with respect to a specific example, that is, children of preschool age presenting to an ED with headache. In this study, as in those reported previously, the overwhelming majority of acute headaches in children and adolescents were attributable to common, minor, transient conditions, such as upper respiratory illness or fever.^{1–5,21} Our study, the largest to date and the only one to focus exclusively on children of preschool age, found, on the basis of initial history and physical examination findings, that 84% of patients had clearly identifiable causes for their headaches. The spectrum of causes of secondary headaches was similar to findings in previous studies, consisting mostly of nonneurologic infectious illnesses. Of the remaining 2- to 5-year-old patients who did not have a clearly identifiable cause for the headache, >1 in 4 underwent CT scanning; the number may be much greater in non-pediatric EDs and in units receiving a primarily tertiary referral population. The only child with abnormal CT scan results in this series would have needed neuroimaging even if he had not had a complaint of headache, because his history indicated several features suggesting increased intracranial pressure and he demonstrated abnormal neurologic examination re-

sults on the day of presentation. In attempting to reconstruct the decision-making process of ED physicians, we observed a tendency to order scans for the youngest children. Given the small numbers, formal statistical analysis was not performed.

CT scanning represents a fast reliable means of diagnosing certain life-threatening conditions that require prompt intervention, notably, intracranial bleeding, tumors, and hydrocephalus. However, CT scans have limited utility in identifying posterior fossa pathologic conditions, cortical dysplasia, acute ischemia, cerebrovascular abnormalities, and other subtle developmental anomalies. For children, CT scans are ordered routinely in the ED not only for headaches but also for various other reasons, including new-onset seizures,²² breakthrough seizures for epilepsy patients,²³ and even simple febrile seizures. In the cases of seizures, developmental delay, and genetic or metabolic encephalopathy, CT scans not only are unhelpful but actually may reassure physicians falsely and delay the ordering of MRI scans, which are much more useful in these clinical situations.

This study and others have demonstrated that the diagnostic yield of CT scans is low for children who present to the ED with headache, nonworrying history, and normal neurologic examination results. Furthermore, the risks associated with CT scanning are not negligible. The risk of cancer from exposure to ionizing radiation is much greater for pediatric patients^{14,24,25} than for older persons, for 2 principal reasons. First, rapidly dividing and developing young tissue is more sensitive to radiation. Second, children have a longer lifetime ahead of them during which radiation-related cancers can develop. For a 5-year old child who undergoes head CT scanning, the lifetime risk of fatal cancer resulting from ra-

diation exposure has been estimated to be ~1 in 2500.¹⁴

The cost of a noncontrast CT scan at our institution is \$1361. In a time of rapidly exploding health care costs, cost is another reason for not ordering this test without clear justification.

ED physicians confronting pediatric headache often are trained in adult care, have no established clinical guidelines to direct them, and work in the presence of considerable parental anxiety. Examination of a young child in pain often is difficult. Therefore, it is not surprising that the diagnostic approach is guided more by a fear of being "less than complete" than by evidence-based medicine.

All previous studies, and now ours, with this youngest population have shown that life-threatening conditions have demonstrable objective findings in the neurologic examination and in most cases also red flags in the history. A previous analysis of data for >3000 children with brain tumors showed that 98% had ≥ 1 of 5 signs (papilledema, ataxia, hemiparesis, abnormal eye movements, or depressed reflexes).²⁶ The value of a thorough neurologic examination cannot be overstated.

Limitations of this study include its ret-

rospective design and lack of complete follow-up monitoring. Analysis was limited to information in clinical records, and it is possible that pertinent history and examination findings were not recorded. We recognize that we might have missed patients who presented with headache and secondary pathologic conditions on CT scans who were assigned a diagnosis other than headache for the visit.

A family history of primary headaches, especially migraine, is one of the strongest predictors of primary headache in preschool-aged children,^{27,28} despite the absence to date of this factor as a criterion in published guidelines. A family history of migraine does not guarantee that a child with a headache has not experienced intracranial hemorrhage, for example, but it does shift the probabilities sufficiently to justify watchful waiting, rather than immediate exposure to radiation, in most cases. However, the majority of children in our study did not have a documented family history or undergo a thorough headache history. For a young child presenting with headache and without any neurologic deficits, a history of migraine or headache in a first-degree relative provides reassurance regarding the benign nature of the headache.

Recent concern regarding identification of unnecessary expenditures in medical care²⁹ gives this study special topicality. Taking a family headache history often is contributory, whereas performing head CT scanning usually is not. CT scanning for young children with headache is expensive, poses risks, and usually is without benefit. Studies such as this one can contribute to recognition of medical interventions for which indications need rethinking.

CONCLUSIONS

For young children presenting to the ED with headache but normal neurologic examination findings and nonworrying history, CT scanning seldom leads to diagnosis or contributes to immediate treatment. A family history often is contributory and should be part of the evaluation of young children with headache in the ED. CT imaging poses risk (which is greatest for the youngest children), is expensive, and usually is without benefit.

ACKNOWLEDGMENTS

This work was supported in part by the Intramural Research Program of the National Institute of Neurological Disorders and Stroke.

REFERENCES

1. Burton LJ, Quinn B, Pratt-Cheney JL, Pourani M. Headache etiology in a pediatric emergency department. *Pediatr Emerg Care*. 1997;13(1):1–4
2. Lobera Gutiérrez de Pando E, López Navarro JA, Youssef Fasheh W, Vernet Bori A, Luaces Cubells C. Headache in a short-stay unit: a retrospective study of 140 cases [in Spanish]. *An Esp Pediatr*. 1999;50(6):562–565
3. Lewis DW, Qureshi FA. Acute headache in the pediatric emergency department. *Headache*. 2000;40(3):200–203
4. Kan L, Nagelberg J, Maytal J. Headaches in a pediatric emergency department: etiology, imaging and treatment. *Headache*. 2000;40(1):25–29
5. Scagni P, Pagliero R. Headache in an Italian pediatric emergency department. *J Headache Pain*. 2008;9(2):83–87
6. Deubner DC. An epidemiologic study of migraine and headache in 10–20 year olds. *Headache*. 1977;17(4):173–180
7. Sillanpää M. Changes in the prevalence of migraine and other headache during the first seven school years. *Headache*. 1983;23(1):15–19

8. Linet MS, Stewart WF, Celentano DD, Ziegler D, Sprecher M. An epidemiologic study of headache among adolescents and young adults. *JAMA*. 1989;261(15):2211–2216
9. Stewart WF, Linet MS, Celentano DD, Van Natta M, Ziegler D. Age and sex-specific incidence rates of migraine with and without visual aura. *Am J Epidemiol*. 1991;134(10):1111–1120
10. Sillanpää M. Prevalence of headache in prepuberty. *Headache*. 1983;23(1):10–14
11. Raieli V, Eliseo M, Pandolfi E, et al. Recurrent and chronic headaches in children below 6 years of age. *J Headache Pain*. 2005;6(3):135–142
12. Lewis DW, Ashwal S, Dahl G, et al. Practice parameter: evaluation of children and adolescents with recurrent headache. *Neurology*. 2002;59(4):490–498
13. Food and Drug Administration. FDA public health notification: reducing radiation risk from computed tomography for pediatric and small adult patients. Available at: www.fda.gov/cdrh/safety/110201-ct.html. Accessed September 29, 2008
14. Brenner DJ, Hall EJ. Computed tomography: an increasing source of radiation exposure. *N Engl J Med*. 2007;357(22):2277–2284
15. Brenner DJ, Elliston CD, Hall EJ, Berdon WE. Estimated risks of radiation-induced fatal cancer from pediatric CT. *AJR Am J Roentgenol*. 2001;176(2):289–296
16. Dooley JM, Camfield PR, O'Neil M, Vohra A. The value of CT scans for children with headaches. *Can J Neurol Sci*. 1990;17(3):309–310
17. Maytal J, Bienkowski RS, Patel M, Eviatar L. The value of brain imaging in children with headaches. *Pediatrics*. 1995;96(3):413–416
18. Lewis DW, Dorbad D. The utility of neuroimaging in the evaluation of children with migraine or chronic daily headache who have normal neurological examinations. *Headache*. 2000;40(8):629–632
19. Alehan FK. Value of neuroimaging in the evaluation of neurologically normal children with recurrent headache. *J Child Neurol*. 2002;17(11):807–809
20. Abu-Arafeh I, MacLeod S. Serious neurological disorders in children with chronic headache. *Arch Dis Child*. 2005;90(9):937–940
21. Rothner AD. Headache emergencies: evaluation, differential diagnosis, and treatment. In: Maria B, ed. *Current Management in Child Neurology*. Hamilton, Canada: Decker; 1998:331–335
22. Freeman JM. Less testing is needed in the emergency room after a first afebrile seizure. *Pediatrics*. 2003;111(1):194–196
23. Allen L, Jones CT. Emergency department use of computed tomography in children with epilepsy and breakthrough seizure activity. *J Child Neurol*. 2007;22(9):1099–1101
24. National Cancer Institute; Society for Pediatric Radiology. Radiation risks and pediatric computed tomography (CT): a guide for health care providers. Available at: www.cancernet.gov/cancertopics/causes/radiation-risks-pediatric-ct. Accessed March 2006
25. Hall EJ. Lessons we have learned from our children: cancer risks from diagnostic radiology. *Pediatr Radiol*. 2002;32(10):700–706
26. Childhood Brain Tumor Consortium. The epidemiology of headache among children with brain tumors. *J Neurooncol*. 1991;10(1):31–46
27. Hernandez-Latorre MA, Roig M. Natural history of migraine in childhood. *Cephalalgia*. 2000;20(6):573–579
28. Battistella PA, Fiumana E, Binelli M, et al. Primary headaches in preschool age children: clinical study and follow-up in 163 patients. *Cephalalgia*. 2006;26(2):162–171
29. Aaron HJ. Waste, we know you are out there. *N Engl J Med*. 2008;359(18):1865–1867

Headache in Young Children in the Emergency Department: Use of Computed Tomography

Tarannum M. Lateef, Mandeep Grewal, William McClintock, James Chamberlain, Himanshu Kaulas and Karin B. Nelson

Pediatrics 2009;124:e12-e17

DOI: 10.1542/peds.2008-3150

Updated Information & Services	including high-resolution figures, can be found at: http://www.pediatrics.org/cgi/content/full/124/1/e12
References	This article cites 26 articles, 11 of which you can access for free at: http://www.pediatrics.org/cgi/content/full/124/1/e12#BIBL
Citations	This article has been cited by 2 HighWire-hosted articles: http://www.pediatrics.org/cgi/content/full/124/1/e12#otherarticles
Subspecialty Collections	This article, along with others on similar topics, appears in the following collection(s): Neurology & Psychiatry http://www.pediatrics.org/cgi/collection/neurology_and_psychiatry
Permissions & Licensing	Information about reproducing this article in parts (figures, tables) or in its entirety can be found online at: http://www.pediatrics.org/misc/Permissions.shtml
Reprints	Information about ordering reprints can be found online: http://www.pediatrics.org/misc/reprints.shtml

American Academy of Pediatrics

DEDICATED TO THE HEALTH OF ALL CHILDREN™

