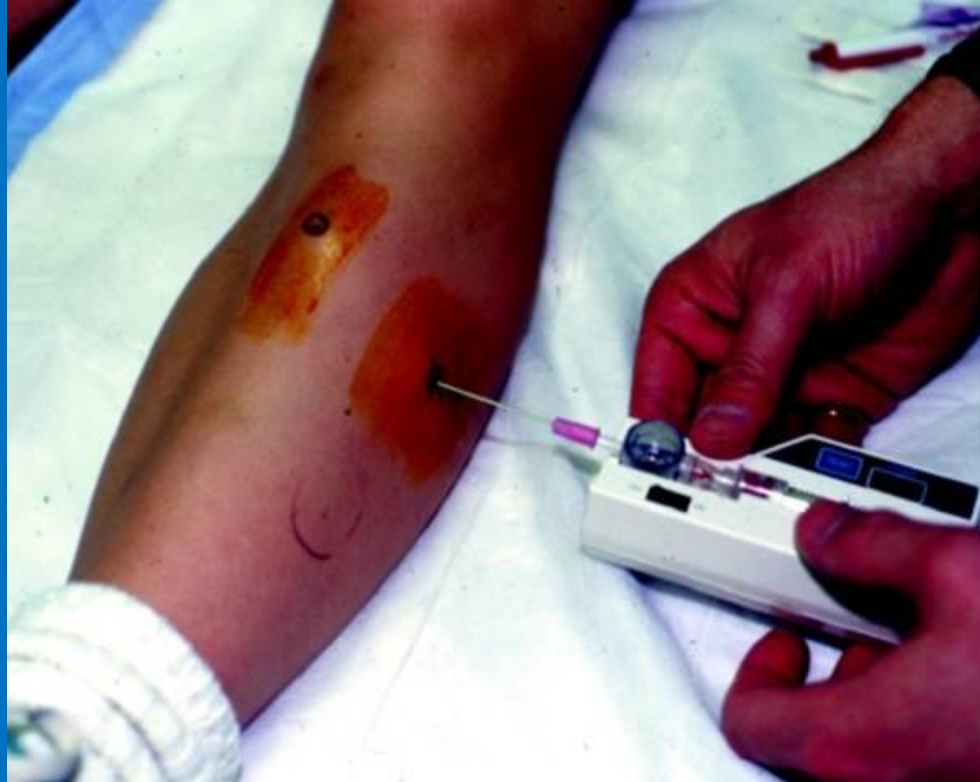

Acute Compartment Syndrome



Stryker measurement - courtesy podiatry today.jpg. orthobullets.com

Case #1

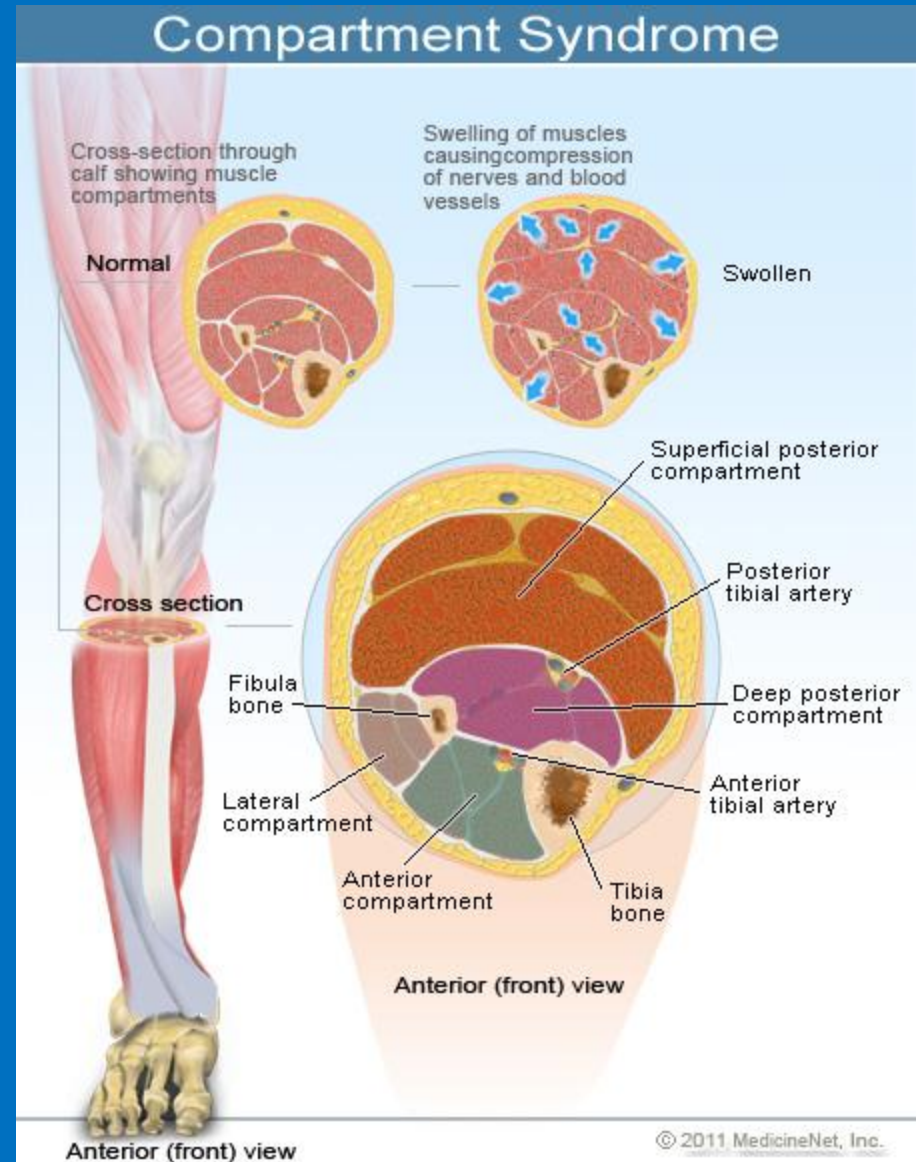
- A 3 yr old male is brought in by the EMS following an accidental gun shot wound to the left leg. You are informed that the patient was found with a bleeding open wound below the tibial tuberosity on a deformed left leg. Leg was warm, well perfused with normal distal foot pulses.
- The EMS team successfully stopped the bleeding by applying a bandage to the wound and calf area. On examination you find a screaming child, with a purple, cold left foot with weak but palpable pulses.
- Question: What would be the first step in the management of this patient?

Multiple Choice

- a) Immediately test for 2 pt discrimination to assist in your suspected diagnosis of compartment syndrome (CS).
- b) Check compartment pressures as it is the criterion standard and is first priority if the diagnosis of CS is in question.
- c) The gun shot has caused an open fracture. CS is less likely; imaging studies must be performed first so as to determine the type and severity of injury.
- d) Release the hemostasis bandages placed by EMS.
- e) Patient has not received any pain medication. IV morphine should be given before any other procedures are performed.

Answer

- d.) Release the Hemostasis bandages first.
- Acute CS occurs when the tissue pressure within a closed muscle compartment exceeds the perfusion pressure and results in muscle and nerve ischemia.



- Cont.) The gun shot wound or open fracture may be the source of hemorrhage and pressure underlying a suspected CS. However, casts/bandages are common iatrogenic causes of early cases of CS. Treatment may entail correction of extrinsic factors such as removal of circumferential bandages .
- Releasing one side of a plaster cast can reduce CS by 30%, bivalving by another 35%, and removing the entire cast an additional 15% for a total of 80% from baseline.

Wrong Answers

- A.) One of the most sensitive and consistent indicators for compartment syndrome is loss of 2 point discrimination, but this is very unreliable in a scared young or non verbal patient.
- B.) After removing the circumferential bandages, if warmth, color, pulses do not improve and CS is still suspected, measurement of intra compartmental pressures remains the std for diagnosis.

- The pressure in compartment syndrome that will be an indication for fasciotomy varies in the literature. Some will use a fixed range of 30-40mmHG. Others will use the delta pressure, or the difference between the patients diastolic BP and the compartment pressure. A delta pressure less than 20-30mmHG would be an indication for fasciotomy.

Wrong Answers

- c.) Open fractures have been found to significantly increase the risk for compartment syndrome. This supports the principle that the fascial disruption from an open fracture does not adequately decompress the compartment.
- The increased energy required to cause an open injury more likely results in extensive tissue damage and swelling within the compartment.
- e.) Pain management is important, but releasing the bandages in this case should be the first step so as to prevent any further ischemia to the tissues.

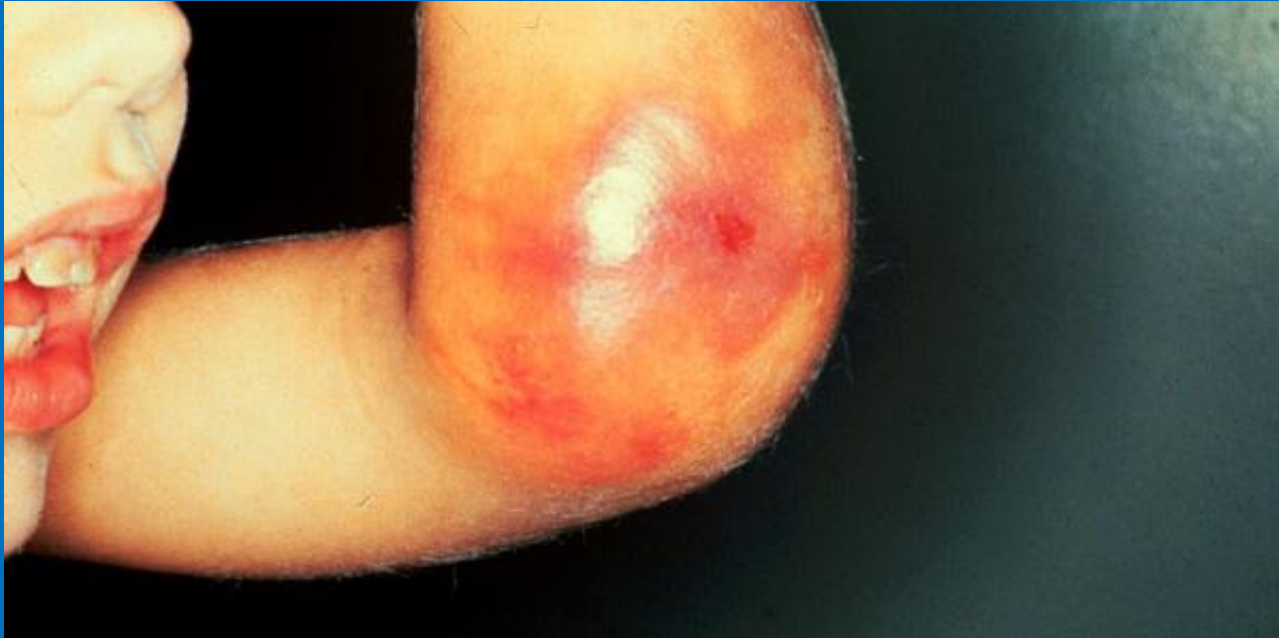References

- B.E Grottkau, H.R. Epps. ***Compartment Syndrome in Children and Adolescents. Journal of Pediatric Surgery*** (2005) 40, 678-682.
- J. Chapman, MD, J Cohen, MD. ***Overview of Tibial Fractures in Children.*** UpToDate Inc. Feb 2010

Case #2

- 5 yr old male presents to the ED with a 3 hour history of pain and swelling of the right arm. The patient's aunt states that he simply twisted his R arm on the monkey bars at the play ground. The pain and swelling gradually became worse over time. She indicates that he has a bleeding problem like all the other males in the family.
- From your history there is no indication of abuse. On examination patient appears to be in severe pain, which is exacerbated by extension of the R fingers. There is swelling and tenseness of the R elbow and forearm with the presence of small blebs on the skin, but there is good capillary refill and a palpable radial pulse.
- What is your approach to the management of this patient?

Case # 2



http://www.uaz.edu.mx/histo/pathology/ed/ch_20a/c20a_sc1.htm

Multiple Choice

- a) You assume the patient has hemophilia A and realize he simply needs Factor VIII infusions
- b) This limb is being compromised but having a bleeding disorder excludes a fasciotomy as part of management so you perform coagulation studies on the patient, and order a routine XRay to make sure there are no fractures of the forearm
- c) You call orthopedic surgeons and prompt them of the need for possible fasciotomy for a suspected compartment syndrome
- d) The patient has good cap refill and pulses so you know you have time to give pain medication before any other steps are made.

Answer

- C) This patient has acute compartment syndrome indicated by the severe pain for a simple twisting injury, pain on extension of the fingers and a tense forearm with blebs on the skin.
- Acute compartment syndrome in a hemophiliac is treated the same as for a non hemophiliac with the addition of infusing factor VIII.
- The appropriate specialists should be informed immediately and steps taken to decompress the arm by fasciotomy as soon as possible.

Wrong Answers

- a) Factor VIII is required but it is only part of the overall management of this patient.
- b) The most effective method of decreasing the pressure within the compartment even in a hemophilic is surgical fasciotomy as long as the appropriate factor replacement is performed
- d) Peripheral pulses can be palpated in many cases of CS; tracing only the pulses can cause a delay in the diagnosis as this is a late sign.

References

- H.A. Caviglia, L.P Solimeno (eds), *Orthopedic Surgery in Patients with Hemophilia. Springer* 2008. pg 260 to 262
- R. R. Madigan, W. T. Hanna, and S. L. Wallace, *Acute Compartment Syndrome in Hemophilia. The Journal of Bone and Joint Surgery Incorporated.* VOL. 63-A, NO. 8. Oct 1981